



AOGD BULLETIN

Volume 19 | October 2019 | Monthly Issue 6 | Price ₹30 Only

**Enlightening the Path
for Next Generation of Gynaecologists**

***Dedicated Issue:*
Minimally Invasive Gynaecological Surgeries**



AOGD SECRETARIAT

Department of Obstetrics & Gynaecology,

3076, Teaching Block, IIIrd Floor, All India Institute of Medical Sciences, Ansari Nagar, New Delhi-110029

Tel.: 011-26546603, 26593221 E-mail: secretaryaogd2019@gmail.com

Website: www.aogd.org

Where Hopes & Wishes come true

IVF Centre, Max Panchsheel Park



Max Panchsheel's IVF programme has been ranked as the First in All India Fertility & IVF Hospital Ranking Survey 2019 by The Times of India Survey 2019 and as the Best IVF Top 10 centres in India by The Week 2018, Best Hospital Survey

OUR SERVICES

In Vitro Fertilization (IVF) | Intra Cytoplasmic Sperm Injection (ICSI) | Male Infertility (Testicular Sperm Extraction/Microtome) | Recurrent Pregnancy Loss | Donor Egg/Sperm | Surrogacy | Fertility Preservation & Oncofertility (Egg, Sperm, Embryo freezing) | Blastocyst Culture | All Fertility Diagnostic Procedure | IUI | PGS/PGD

TEAM THAT CARES

- **Dr. Surveen Ghumman Sindhu** (Director & Head)
- **Dr. Bhavna Banga** (Associate Director)
- **Dr. Tanya Buckshee Rohatgi** (Principal Consultant)
- **Dr. Shalini Chawla** (Senior Consultant)
- **Dr. Richa Singh** (Senior Consultant)

FELLOWSHIP IN REPRODUCTIVE MEDICINE

Ongoing Post-Doctoral Fellowship Program in IVF & Reproductive medicine covering clinical & embryological aspects in ART (1 year).

Course Director:

Dr. Surveen Ghumman

Course Coordinator:

Dr. Shalini Chawla Khanna

REGISTRATION OPEN FOR NEW BATCH: To register, call Dr Siddharth Prasad on +91 70115 17261, 98734 23518

Because at Max Healthcare, we are eager to get you home.



Max Multi Speciality Centre, Panchsheel Park

N - 110, Panchsheel Park, New Delhi-110 017, Phone: +91-11-4609 7200, www.maxhealthcare.in

AOGD Bulletin

Volume 19 • Monthly Issue 6 • October 2019

AOGD Executive Committee 2019-20

President

Dr Sunesh Kumar

Vice President

Dr Ashok Kumar

Hony. Secretary

Dr Vatsla Dadhwal

Scientific Advisors

Dr Dipika Deka
Dr Neerja Bhatla
Dr K K Roy
Dr Neena Malhotra

Treasurer

Dr Rohini Sehgal

Editor

Dr J B Sharma

Web Editor

Dr Juhi Bharti

Joint Secretaries

Dr K Aparna Sharma

Co-Editors

Dr Reeta Mahey
Dr Vanamail

Clinical Secretaries

Dr Vidushi Kulshreshtha
Dr Rajesh Kumari

Scientific Committee

Dr Neeta Singh
Dr Garima Kachhawa
Dr Seema Singhal
Dr Jyoti Meena

Finance Committee

Dr Reva Tripathi
Dr N B Vaid
Dr Manju Puri
Dr Abha Singh
Dr Sunesh Kumar
Dr Shalini Rajaram
Dr Sudha Prasad
Dr Pratima Mittal
Dr U P Jha
Mr Pankaj (CA)

Executive Members

Dr Anita Sabharwal
Dr Achla Batra
Dr Asmita Rathore
Dr Bela Makhija
Dr Dinesh Kansal
Dr Gauri Gandhi
Dr Indu Chawla
Dr Kiran Guleria
Dr Manash Biswas
Dr Manju Khemani
Dr Manju Puri
Dr Mala Srivastava
Dr Ranjana Sharma
Dr Renu Mishra
Dr Reva Tripathi
Dr Rupali Dewan
Dr S N Basu
Dr Sangeeta Gupta
Dr Shalini Rajaram
Dr Suman Lata

AOGD Secretariat

Department of Obstetrics and Gynecology
3076, Teaching Block, IIRd Floor
All India Institute of Medical Sciences, Ansari Nagar, New Delhi 110029
Tel No: 011-26546603, 26593221
Email: secretaryaogd2019@gmail.com
www.aogd.org

Patrons

Dr D Takkar
Dr Kamal Buckshee
Dr Neera Agarwal
Dr Sheila Mehra
Dr S K Bhandari
Dr S N Mukherjee
Dr Swaraj Batra
Dr Urmil Sharma
Dr V L Bhargava

Advisors

Dr Alka Kriplani
Dr Amita Suneja
Dr Chitra Raghunandan
Dr Pratima Mittal
Dr SB Khanna
Dr Sharda Jain
Dr Shubha Sagar Trivedi
Dr Sudha Salhan
Dr Suneeta Mittal
Dr Usha Manaktala

Ex Officio

Executive Past Presidents

Dr P Chadha (1990-94)
Dr Neera Agarwal (1994-97)
Dr Maya Sood (1997-99)
Dr D Takkar (1999-2001)
Dr Sudha Salhan (2001-03)
Dr Swaraj Batra (2003-05)
Dr N B Vaid (2005-06)
Dr S S Trivedi (2006-07)
Dr Suneeta Mittal (2007-08)
Dr I Ganguli (2008-09)
Dr Shashi Prateek (2009-10)
Dr U Manaktala (2010-11)
Dr Neerja Goel (2011-12)
Dr C Raghunandan (2012-13)
Dr Alka Kriplani (2013-14)
Dr U P Jha (2014-15)
Dr Pratima Mittal (2015-16)
Dr Sudha Prasad (2016-17)
Dr Shalini Rajaram (2017-18)

Immediate Past President (2018-2019)

Dr Abha Singh

Immediate Past Secretary (2018-2019)

Dr Kiran Aggarwal

President Elect (2020-2021)

Dr Mala Srivastava

Vice President FOGSI

Dr Sudha Prasad

Chairpersons

AOGD Sub-Committees

Dr Manju Khemani
Dr Manju Puri
Dr Amita Suneja
Dr Achla Batra
Dr Kiran Aggarwal
Dr Anita Rajorhia
Dr Jyotsna Suri
Dr Manisha Kumar
Dr Reema Bhatt
Dr Richa Sharma
Dr Susheela Gupta
Dr Surveen Ghuman
Dr Abha Sharma
Dr A G Radhika

President

Dr Sunesh Kumar

Vice President

Dr Ashok Kumar

Hon. Secretary

Dr Vatsla Dadhwal

Contents

- **Peritoneal Access in Laparoscopic Surgery** 7
Rakhi Rai, Anamika Das, Vidushi Kulshreshtha
- **Laparoscopic Ovarian Drilling** 14
Malvika Sabharwal, Shivani Sabharwal, Nupur Chhabra, Swati Rai
- **Laparoscopy in Endometriosis** 19
Rakhi Rai, Kallol Kumar Roy, Vinod Nair, Vidushi Kulshreshtha
- **Specimen Retrieval in MIGS** 35
Vinod Nair, Garima Kachhawa, Rakhi Rai, Archana Minz
- **Minimally Invasive Surgeries in Gynaecological Oncology** 39
Jayashree N, Neerja Bhatla
- **Introduction to Robotics** 44
Vinod Nair, Kallol Kumar Roy, Anamika Das
- **Scar Ectopic Pregnancy** 48
Dinesh Kansal, Pooja Gupta
- **Office Hysteroscopy Revisited** 52
Shikha Sharma, Anamika Das, Sadia Mansoor, Kallol Kumar Roy
- **Journal Scan** 56
Preeti Deedwania, Nilofar Noor
- **The Maze of Knowledge and Pictorial Quiz** 58
Garima Patel, Vidushi Kulshreshtha

Disclaimer

The advertisements in this bulletin are not a warranty, endorsement or approval of the products or services. The statements and opinions contained in the articles of the AOGD Bulletin are solely those of the individual authors and contributors, and do not necessarily reflect the opinions or recommendations of the publisher. The publisher disclaims responsibility of any injury to persons or property resulting from any ideas or products referred to in the articles or advertisements.

Plagiarism Disclaimer

Any plagiarism in the articles will be the sole responsibility of the authors, the editorial board or publisher will not be responsible for this.

Publisher/Printer/Editor

Dr J B Sharma on behalf of Association of Obstetricians & Gynecologists of Delhi.

Printed at

Process & Spot C-112/3, Naraina Industrial Area, Phase-1, New Delhi 110 028

Published from

Department of Obstetrics and Gynecology
All India Institute of Medical Sciences, Ansari Nagar, New Delhi 110029

Editor

Dr J B Sharma
Ph. No. 011-26546603; Email: secretaryaogd2019@gmail.com

Total number of pages = 60

From the President's Pen



It gives me immense pleasure to present to all this monthly bulletin devoted to endoscopy in gynaecology. We have travelled a long way from doing diagnostic laparoscopies and tubal ligation to most complex surgeries. As one acquires more and more expertise, it seems almost all surgeries will be possible by laparoscopic approach.

This month also witnessed hosting of 41st Annual Conference of AOGD on 28th & 29th September, 2019. With active participation by all, this scientific activity was well appreciated.

I wish a very happy Deepawali and other festivals in coming months.

Dr Sunesh Kumar
President, AOGD

From the Secretary's Desk



Dear friends

Thank you all for the stupendous response, 41st Annual Conference was a huge success with 700 registrations. This was possible because of the love and support of each and every AOGD member. There were 9 well attended Precongress Workshops.

I take this opportunity to again thank all the Delegates and Faculty for their inputs. I am grateful to the AOGD Office bearers at AIIMS, my Seniors and Junior Colleagues, for their effort and support in making a rich scientific programme and in organization of the annual conference. There were 150 abstracts for paper presentation.

Walkathon for safe abortion on 29th Sept was well attended.

The current issue of the Bulletin is dedicated to Minimally Invasive Surgery. It covers the basics of MIS as well as latest advances like MIS in oncology surgery and Robotic surgery.

A CME was organized on “Update on Surgical Wound Management”, under aegis of Multidisciplinary Committee of AOGD and FOGSI Clinical Research Committee on 7th Sept.

We look forward to your continued support.

Warm regards.

Dr Vatsla Dadhwal
Hon. Secretary

Monthly Clinical Meeting

Monthly Clinical Meet will be held at ESI Hospital, New Delhi
on **Friday, 25th October, 2019 from 04:00pm to 05:00pm.**

From the Editor's Desk



Prof K K Roy
Guest Editor



Dr J B Sharma
Editor



Dr Reeta Mahey



Dr P Vanamail
Co-Editors



Dr Vidushi Kulshreshtha

Dear esteemed AOGD members

It is a great pleasure to release the next issue of AOGD bulletin on “Minimally Invasive Gynaecological Surgery”. This MIGS dedicated issue is ably edited by Prof KK Roy and his team. Laparoscopy is an art with a significant learning curve. This issue is a mixed bag of academic bonanza covering vast topics of MIS. The laparoscopic surgery is the need of the hour.

Peritoneal access in laparoscopy by Dr Rakhi and Dr Vidushi will help young budding gynaecologists to build up their skills in safe peritoneal entry and how to tackle the special situations like previous surgery, obesity, previous hernia repair etc.

Dr Malvika Sabharwal and team evaluated laparoscopic ovarian drilling in PCOS patients. Laparoscopic ovarian drilling is an alternative approach to treat anovulatory polycystic ovary syndrome (PCOS) patients, although its indications are yet not well defined. Patients with poor response to hormonal stimulation or disagreement with repeated multifollicular reaction to gonadotrophin stimulation might benefit from the surgical approach.

Endometriosis is always a topic of therapeutic dilemma. Various guidelines regarding management and different surgical techniques to minimise ovarian loss are outlined in the article by Dr KK Roy and Dr Rakhi.

Dr Shikha & team discussed about the office hysteroscopy making hysteroscopy simpler for the beginners.

Dr Jayashree and Dr Neerja Bhatla have extensively reviewed the role of minimally invasive gynaecological surgery in oncology and found it to be an evolving subject with topics of arguments over decades. Optimal patient selection, adequate counselling, expertise and adherence to oncological principles will provide good outcome.

Caesarean scar pregnancy is but a gradually increasing problem due to increase in caesarean rates with a diagnostic and therapeutic challenge. Dr Dinesh Kansal and team elaborated its diagnosis and management achieving optimal outcome.

Laparoscopy is a continuous learning process. Specimen retrieval in MIGS is a challenging task. The pros and cons of various tissue retrieval methods was discussed by Dr Vinod Nair and Dr Garima Kachhawa.

Robotic surgery is the latest addition to armamentarium of minimally invasive gynaecological surgery. As it is a recent surgical technique in the field of MIS, it is prudent to have in depth knowledge of robotic instrumentation and surgical techniques involved in it which is well enlightened by Dr Vinod Nair and Prof KK Roy.

Interesting journal scan has been done by Dr Preeti on important research papers on MIS.

We hope this bulletin will enlighten the path of our colleagues by enriching their knowledge and skills and will help them to tackle the challenges in day to day practice. We welcome the comments and views of our readers which will help us to improve our future bulletins.

The editorial team wish you all success in all your endeavours.

Editor

Dr J B Sharma

Guest Editor

Prof K K Roy

Peritoneal Access in Laparoscopic Surgery

Rakhi Rai¹, Anamika Das², Vidushi Kulshreshtha³

¹Fellow, MIGS, ²Senior Resident, ³Associate Professor, Department of Obstetrics & Gynaecology, AIIMS New Delhi

Introduction

Laparoscopy has revolutionized the surgical field in the present era. Laparoscopy (Laparo – abdomen, scopein – to examine) is a way to examine the abdomen.

There are two types of port insertion methods. First generation or conventional trocar-cannula method is based on the principle of cutting technique i.e. transecting all anterior abdominal wall layers with a linear force whereas second generation port insertion method involves port insertion under vision using radial spin principle. It involves use of hollow threaded cannula with blunt tip without central trocar. Tissue layers are pushed aside radially.

Methods of peritoneal access

Open access (Hasson Technique)- The abdominal wall is dissected upto rectus fascia and direct trocar is inserted without pre-insufflation with veress needle.

Dingfielder first introduced direct trocar technique in 1971. According to Dingfielder, proper abdominal wall relaxation, adequate skin incision and sharp trocar are the keys to successful direct trocar insertion. It is safe alternative to veress needle. It is a fast and efficacious method of entry to peritoneal cavity without prior pneumoperitoneum.

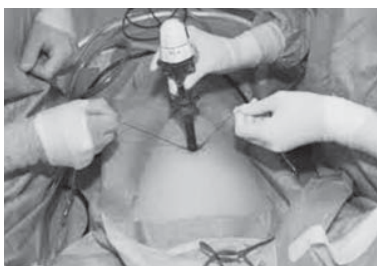

Fig 1: Open Access Technique showing direct trocar insertion

Closed access-

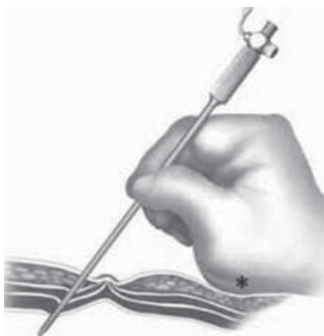

Fig 2: Closed access method showing veress needle insertion

Insufflation is done with veress needle followed by trocar insertion. The advantages are quick entry into peritoneal cavity as direct cutdown of fascia is not required and reduced chances of hernia formation. The major disadvantage is increased chance of vascular injury as distance between base of umbilical stalk and aorta is less than 4cm and even as less as 2cm in thin patients. 2pops are felt, first at level of fascia and second when it enters peritoneal cavity.

According to Cochrane 2019, open entry technique has a lower failed entry rate with no effect on visceral injury as compared to veress needle insertion but the evidence was of low quality.

EndoTIP is endoscopic threaded imaging port, developed by Ternamian. It is a reusable visual access cannula. It can be used for open or closed access laparoscopy. During removal of EndoTIP trocar, abdominal wall tissues recoil back to their place to close port site. The various indications of EndoTIP are previous abdominal surgery with suspected adhesions, vague lower abdominal symptoms, retroperitoneal surgeries, endometriosis, obese patients with history of previous failed laparoscopy, previous > 1 laparoscopy and conditions necessitating under vision port insertion like pregnancy & large tumors. The major advantage of EndoTIP is that the wrong insertion of port can be detected immediately and be corrected also at same time avoiding major injury.




Fig 3: Endo TIP Port

Position During Laparoscopy

Lithotomy position with boot stirrups is preferred as it allows vaginal manipulation or mobilization of uterus/vault easy. The operating table should be at lowest position. Non-slip mattress or beanbags should be used to prevent slippage of patients when patient is in head down position. Special attention should be paid to pressure points like elbow or wrist while using a beanbag.

Veress Needle Placement

Veress needle placement into peritoneal cavity can be confirmed by various ways:

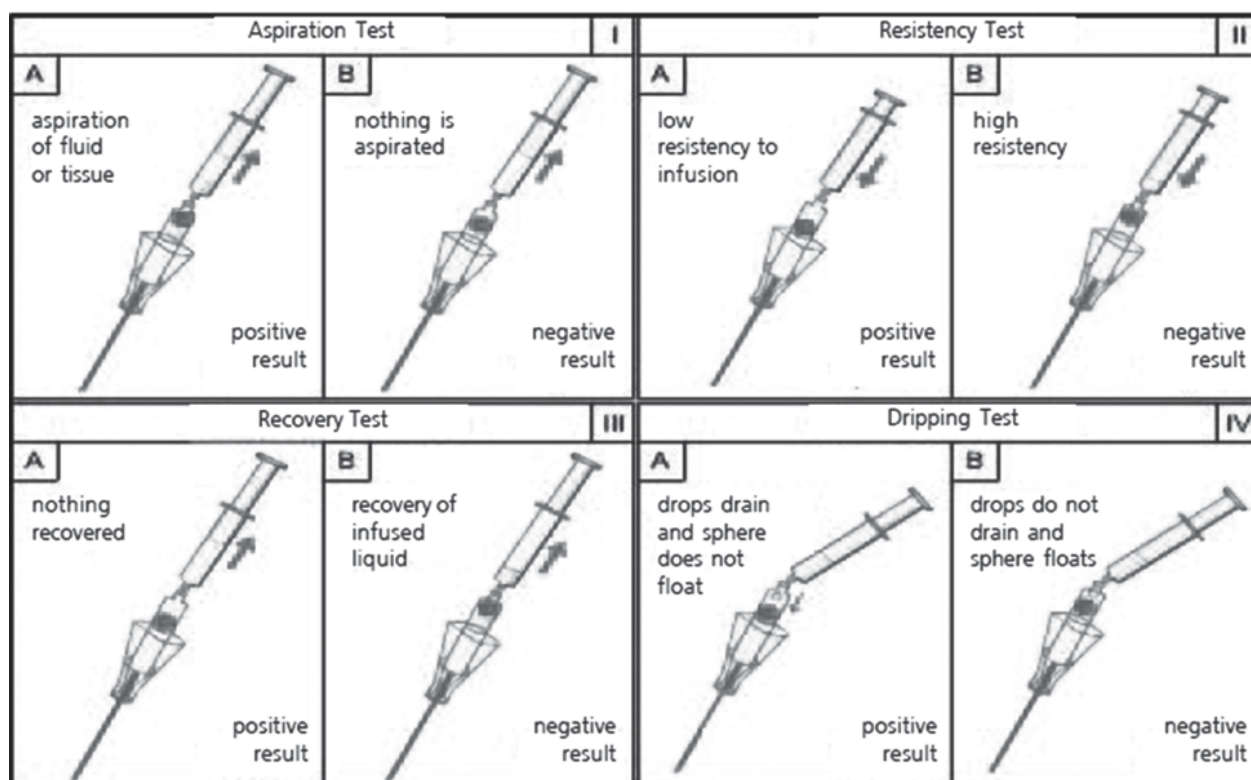


Fig 4: showing ways to access correct placement of veress needle

Saline Injection and Aspiration Method

Attach the saline filled syringe to veress needle and aspirate. If blood or fecal matter is aspirated, it indicates that needle is in vessel or bowel respectively. Leave needle in situ and identify the site of injury from another abdominal access site.

Inject saline into the veress needle. If saline goes freely without any resistance, it indicates intraperitoneal placement of needle.

Hanging Drop Method

Place a drop of saline over open hub of veress needle. Lift the abdominal wall. Absorption of saline drop due to negative intraabdominal pressure created indicates correct placement of needle.

Intra-abdominal pressure- Veress needle placement is confirmed if intraabdominal pressure is ≤ 10 mm Hg

According to Cochrane 2012, risk of failed veress needle entry is less if anterior abdominal wall is not lifted. Risk of complications increase as the number of attempts of veress needle insertion increases i.e 16.3% with 1st attempt which rises to 84.6% with more than 3 attempts.

After confirmation of intra-abdominal placement of veress needle, gas insufflation is started. Once

pneumoperitoneum is established, primary trocar is placed preferably under vision. Holding the trocar from shaft rather than the top helps to control speed and depth of penetration of trocar.

Veress needle with radially dilatable expandable sleeve like versa step is also available. Trocar can be inserted through sleeve, which maintains track after creation of pneumoperitoneum and removal of veress needle preventing the change in direction from that of needle entry.

Hissing sound of gas indicates adequate depth of trocar insertion has reached. Withdraw the trocar and further insert cannula by 1-2 cm. Insert laparoscope through trocar and examine the abdomen.

Hyperdistension of abdomen is highly useful as it elevates the abdominal wall from internal abdominal organs thereby preventing injury to them. It is especially useful in thin and obese patients.

Visual Entry Technique for Port Placement

The optical trocar is inserted under vision with 0 degree laparoscope traversing and visualizing each layer of abdominal wall thereby minimizing the chances of injury to vessels or viscera. The available optical trocars are optiview, visiport and kii optical system.

Access Sites

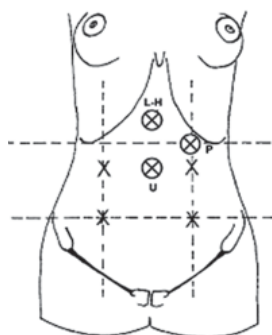


Fig 5: Access sites for port entry

Umbilicus- It is the most common site for access to pneumoperitoneum as this area is thin due to absence of fat and muscle between skin and peritoneum. Alternative access site should be considered in the presence of umbilical hernia or urachal anomaly.

Medial costal margin- for upper abdominal surgery

Lateral abdomen/ flank – used for insertion of retraction instruments. It is inserted 2 finger breadths medial and superior to anterior superior iliac spine.

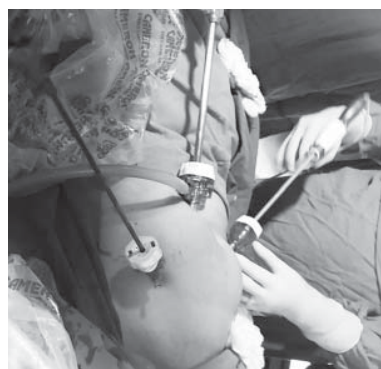

Fig 6: lateral port placement

Palmer's point- It is 3cm below left costal margin in the midclavicular line just lateral to rectus muscle. It can be used for veress needle insertion for insufflation. Veress needle is always inserted at 90° irrespective of patient's weight. It is used in cases of previous midline laparotomy, multiple failed attempts of port insertion at umbilicus, extremely obese or thin patients or pelvic mass extending till umbilicus.

Lee Huang Point- It lies between umbilicus and xiphoid process and used for primary port insertion in case of suspected umbilical adhesions due to previous surgery or large abdominopelvic masses.

9th intercostal space- It is accessed in anterior axillary line close to superior border of 10th rib and is used for primary insufflation with veress needle. The splenic flexure of colon and inferior margin of spleen are nearby, hence access is a difficult task.

Hypogastrum- It is used in case of surgery on pelvic structures. Many vessels and nerves lie in this area i.e. inferior & superficial epigastric arteries, superficial and deep circumflex iliac arteries, iliohypogastric and ilioinguinal nerves. Hence port insertion just superior and medial to anterior superior iliac spine avoids these structures.

Special Situations

Umbilical Hernia

In case of small umbilical hernia, open access the hernia, adhesions should be cleared by finger and hernia repair should be done at the end.

Prior Abdominal Surgery

Avoid prior incision site for initial access. If it is necessary to go through previous incision, use open access. After placement of initial port, abdomen should be visualized for adhesions before putting additional ports.

Obesity

- The operating table should be wide enough to allow arms of patient to be tucked in by the sides, which prevent injury to brachial plexus/ ulnar nerve. Also it removes use of arm board to support arms, which may interfere with surgeon's operating space. Shoulder braces should be avoided in trendelenberg position as it may cause brachial plexus injury.
- Use longer veress needle/ trocars because of increased abdominal wall thickness. Entry should be based on bony landmarks not umbilicus in case of veress needle technique.
- Skin folds should be avoided
- Veress needle should be inserted at 90 degree to maximally utilize veress needle length.
- Dilating trocars use may decrease the incidence of postoperative hernia.
- Nasogastric tube should be put to relieve gastric distension prior to veress needle insertion.
- Palmer's point is safe for insufflation with less failure rate.
- Usually ports need to be inserted more superior than non-obese patients.
- It is difficult to reposition port once dislodged; hence intraabdominal inflatable balloon & extraabdominal stabilizer helps to prevent displacement of port
- Angled laparoscopes may give better visual access to certain areas.
- Ligation of vessels at the beginning of surgery prior

to division is useful for better visualization.

- Pelvic drain can be inserted to prevent any collection & subsequent infection
- Vault closure by vaginal approach can be used.

Pregnancy

Avoid access through uterus

Open access is advocated

Advanced Access Techniques

Single incision laparoscopic surgery (SILS)/Laparo-endoscopic single site surgery (LESS)

Uses single incision, mainly at umbilicus

The main contraindication is previous hernia repair with mesh placement at access site.

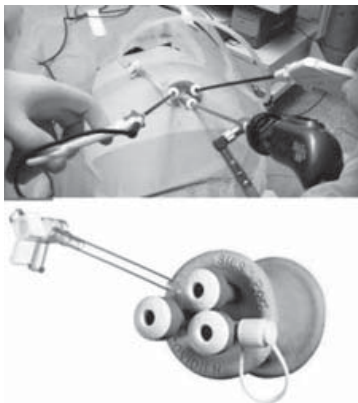


Fig 7: Single Incision Laparoscopic Surgery and Port

Challenges of SILS

- Loss of depth perception as all working instruments and camera are parallel to each other
- Decreased range of movement of instruments
- Hand clashing problem due to reduced extraabdominal working space
- Reduced field of vision because of suboptimal position of camera or instruments

Establishing Pneumoperitoneum

Ideal gas for creating pneumoperitoneum should be cheap, non-flammable, easily available, colourless, non toxic, non explosive and easily removable by the body.

Gases used

CO₂ is the most commonly used gas.

Helium / nitrous oxide / room air can be used, safety not proven. Helium and argon are less soluble; hence there is increased chance of venous gas embolism. Risk of explosion with nitrous oxide is controversial. Room air is associated with lower hospital cost.

CO₂ is near to ideal gas as it has low cost, non-flammable, chemically stable and high diffusion capacity with rapid absorption & excretion but it is not a perfect gas. CO₂ absorption may lead to hypercapnia & acidosis that is to be prevented by hyperventilation. It may lead to cardiac arrhythmias, tachycardia and pulmonary edema. It may cause peritoneal irritation leading to postoperative pain. It may cause immunological impairment.

Preoperative hypothermia may lead to myocardial ischemia & cardiac arrhythmias like ventricular tachycardia, generalized immunosuppression & infection due to decreased oxygen supply to healing tissues as a result of peripheral vasoconstriction and increased blood loss. According to Cochrane review, heating or humidifying CO₂ has no extra benefit in improving patient outcome or surgical care than cold gas insufflation. Combination of heated humidified CO₂ and forced air warming blanket is helpful for maintaining body temperature but further human studies are needed.

Initially CO₂ flow rate is kept low. After confirmation of abdominal insufflation, flow rate is increased. The pressure will be initially < 10 mmHg but will gradually increase. The preset intraabdominal pressure is 12-15mm Hg. Gas will flow only if pressure is below preset intraabdominal pressure. If pressure rapidly builds to 12-15mmHG, it indicates that either needle/trocar is displaced or occluded. Lifting the abdominal wall or changing the angle or rotation of trocar or needle may dislodge the bowel or omentum, which may be blocking the needle or trocar.

Ensure the correct position of stopcock for passage of gas and there is no kinking of gas tubing. If nothing of above works, remove needle or port and reinsert.

As intra-abdominal pressure increases with pneumoperitoneum, neurohumoral vasoactive mechanism got activated which may lead to increase in heart rate, systemic or pulmonary vascular resistance and mean arterial pressure. Vital capacity, venous return, preload, venous return and cardiac output decreases. In ASA class 1 & 2 patients, these effects are not harmful if pressure doesn't exceed 15mm Hg.

CO₂ pneumoperitoneum has chemical and mechanical effects on cardiovascular system. Pneumoperitoneum causes compression of vena cava leading to decreased venous return, decreased cardiac output and increased central venous pressure causing rise in vascular resistance in arterial circulation. It can be managed by adequate fluid replacement. Tachycardia can occur secondary to sympathetic stimulation, hypercarbia

and decreased venous return. Hypercarbia moderate to severe may lead to ventricular contraction, ventricular tachycardia or ventricular fibrillation. Vagal stimulation due to peritoneal stretching may lead to bradyarrhythmias. Above effects can be prevented by maintaining low intraabdominal pressure to ≤ 12 mm Hg and adequate hydration. End tidal CO₂ should be monitored. Trendelenberg position used during laparoscopy may increase the preload by increasing the venous return from lower extremities. It also causes cephalad shifting of viscera causing pressure on diaphragm. In case of reverse trendelenberg, there is decreased venous return resulting in hypotension. There is caudal shifting of viscera releasing pressure on diaphragm increasing tidal volume of lungs. Pooling of blood in lower extremities may increase the risk of deep venous thrombosis.

Pneumoperitoneum increases the intraabdominal pressure leading to elevation of diaphragm resulting in basal lung collapse thereby decreasing functional residual capacity, impaired ventilation perfusion ratio, raised intrapulmonary blood shifting resulting in hypoxaemia. These effects can be managed by raised frequency of mechanical ventilation with mild positive end expiratory pressure (PEEP) & by increasing inspired oxygen during laparoscopy. PEEP of 5cm H₂O should be maintained to reduce intraoperative atelectasis due to pneumoperitoneum. It raises FRC improving gas exchange oxygenation.

Complications of Laparoscopic Access

Complications related to initial abdominal access occurs in < 1% of patients.

Vascular injury- The rate of vascular injury is 0.1-6.4 per 1000 laparoscopic surgeries. Most commonly occurs at entry of veress needle or trocar. Major vessel injuries include injuries to aorta, inferior vena cava or iliac vessels. Minor vascular injuries include injuries to vessels of abdominal wall, mesentery or other organs. Most common is the injury to inferior epigastric vessels, usually during secondary port placement especially if trocar is not placed under vision or abdominal wall was not illuminated prior to insertion. It can present as abdominal pain, flank ecchymosis, bleeding from trocar site or hemodynamic instability. Inferior epigastric artery injury shall be managed with bipolar coagulation. If bleeding is not controlled by coagulation, foley's balloon tamponade should be attempted, if bleeding gets controlled remove foley's after 6 hrs. If still bleeding persists, inferior epigastric artery should be ligated. Bleeding at port site might be obscured with ports in situ and

insufflated abdomen due to tamponade but may result in delayed bleeding or abdominal wall hematomas. If abdominal wall hematoma was found at later stage and patient is hemodynamically stable then conservative management should be adopted. If patient is hemodynamically unstable or expanding hematoma or hematoma gets infected, surgical approach should be adopted. Percutaneous embolization of bleeding vessel can also be attempted. Aortic injury is very rare. It should be managed by multidisciplinary team. Veress needle must be left in situ and one should proceed with resuscitation and immediate laparotomy.

Bowel Injury

Bowel injury commonly occurs at the time of laparoscopic entry of trocar or veress needle. It occurs in 0.03-0.18% of patients undergoing laparoscopic surgery. Small bowel is the most common site of injury but stomach, colon, liver may also get injured especially in subcostal insertions. Many of bowel injuries go unrecognized intraoperatively and usually patients present with peritonitis following discharge. Free intraabdominal gas as a sign of gut injury is not helpful after laparoscopic surgery as > 2cm free air may be present in 40% patients at 24 hours. It may be seen even upto 1 week postoperatively but the amount of gas usually decreases with time. Gut injury should be suspected if volume of gas is increasing over period of time. In electrosurgical gut injuries, margins of gut should be inverted and sutured to healthy tissue. Resection anastomosis may be required if extent of injury is large. The diagnosis of delay is a major cause of morbidity and mortality. Injury with veress needle can be managed conservatively whereas trocar injuries can usually be managed by bowel approximation by simple suturing, rarely colostomy is required.

Bladder Injury

Bladder injury is rare during laparoscopy. Most commonly it occurs during laparoscopic access (insertion of primary or secondary trocar insertion). Prior pelvic surgery is a major risk factor. Patient should be made to pass urine prior to surgery and foley's catheter should be inserted to deflate bladder to prevent injury. It will also help to detect the bladder injury early intraoperatively. Gaseous distension of urinary bag and hematuria indicates bladder injury. It can be detected by instillation of methylene blue or indigo carmine dye in bladder. Bladder injury by veress needle may be left for conservative management. Larger irregular defects should be closed by absorbable sutures.

Nerve Injury

Port insertion should be done carefully avoiding nerves. It is not recognized intraoperatively and leads to persistent postoperative pain.

Hernia

Facial closure is required in open access or port size ≥ 12 mm. Port sites at site of previous mesh should be closed with permanent suture.

Risk of incisional hernia is rare in laparoscopic surgery, incidence being 1.9 and 3.2% at 2 years & 5 years respectively post surgery. It is more common with use of multiple ancillary ports, larger ports for specimen retrieval or staple devices or single site surgery. Old age, high BMI, increased operative time and excessive manipulation are the risk factors. Incidence of hernia is less with ≤ 12 mm ports and radially dilating trocars. It may manifest as gross disruption of wound, bulge with exertion or valsalva, continuous pain if bowel or omentum got incarcerated in it. Hernias may develop at extraction site, commonly midline. Hence, site away from midline should be chosen for extraction. Once hernia is detected site should be repaired to prevent intestinal complications.

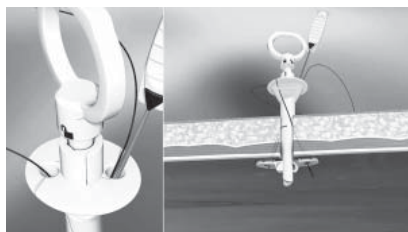


Fig 8: Weck EFX™ Endo Fascial Closure System

Wound Infection

It is less common after laparoscopic surgery than open surgery. Umbilicus is the commonest site but is correlated with specimen retrieval. It presents with discharge from wound site, pain and fever. It is treated with antibiotics and local wound care.

Complications Related to Pneumoperitoneum

Subcutaneous and mediastinal emphysema (due to improper placement of veress needle or port), pneumothorax, cardiac arrhythmias, air embolism due to venous injury and shoulder pain.

Complications Related to Tissue Dissection And Hemostasis

Electrosurgical injuries can occur during laparoscopic surgery. Vessel, bladder, ureteric and bowel injuries can occur. Visible thermal injury is always less than actual injury.

Ureteric Injury

Ureteric injury can occur either during difficult dissection or by thermal energy. The best way to prevent ureteric injury is by identification of ureter by anatomic landmarks and by peristalsis. In case of difficult surgeries, ureter should be dissected and mobilized. Surgeon should confirm the integrity of ureter at the end of surgery.

Port Site Metastasis

Port site metastasis means growth of malignancy at port site. It occurs in 1-2% of laparoscopic procedures for intraperitoneal malignancy. It can occur as early as 10 days postoperatively. Different mechanisms have been proposed for port site metastasis like direct spread of tumor cells, hematogenous spread, surgical technique and secondary to pneumoperitoneum. It can be prevented by use of specimen retrieval bag or wound protectors, port excision and instillation of agents to prevent tumor growth.

Laparoscopy is now common modality for various surgical procedures. The proper selection of patients, knowledge of surgical anatomy and correct careful abdominal access are keys to successful laparoscopic surgery

Suggested Reading

1. Palmer R. Safety in laparoscopy. *J Reprod Med* 1974; 13:1.
2. Quilici PJ, Greaney EM, Quilici J, Anderson S. Transabdominal preperitoneal laparoscopic inguinal herniorrhaphy: results of 509 repairs. *Am Surg* 1996; 62; 849
3. Teoh B, Sen R, Abbott J. An evaluation of four tests used to ascertain veress needle placement at closed laparoscopy. *J Minim Invasive Gynecol* 2005; 12: 153.
4. Shirk GJ, Johns A, Redwine DB. Complications of laparoscopic surgery: How to avoid them and how to repair them. *J. of Minim Invasive Gynecol* 2006; 13: 352.
5. Rahn DD, Phelan JN, Roshanravan SM et al. Anterior abdominal wall nerve and vessel anatomy; clinical implications for gynaecologic surgery. *Am J of Obstet Gynecol* 2010: 202-234.
6. Gill IS, Advincula AP, Aron M et al. Consensus statement of the consortium for Laparoendoscopic single site surgery. *Surg Endosc* 2010; 24: 762.
7. Ahmad G, O'Flynn H, Duffy JM. et al. Laparoscopic entry techniques. *Cochrane Database Syst Rev* 2012: CD006583.
8. Thepsuwan J, Huang KG, Wilamarta M, Adlan AS, Manvelyan V, Lee CL. Principles of safe abdominal entry in laparoscopic gynecologic surgery. *Gynecology and Minimally Invasive Therapy* 2013;2: 105-109
9. Ahmad G, Gent D, Henderson D. et al. Laparoscopic entry techniques. *Cochrane Database Syst Rev* 2015; 8: CD006583.
10. Hackethal A, Brennan D, Rao A, Land R, Obermair

- A, Nicklin J, Garrett A, Nascimento M, Crandon A, Perrin L, Chetty N. Consideration for safe and effective gynaecological laparoscopy in the obese patient. *Arch Gynecol Obstet* 2015; 292:135–141.
11. Yu T, Cheng Y, Wang X, Tu B, Cheng N, Gong J, Bai L. Gases for establishing pneumoperitoneum during laparoscopic abdominal surgery (Review). *Cochrane Database of Systematic Reviews* 2017, Issue 6. Art. No.: CD009569. DOI: 10.1002/14651858.CD009569.pub3. Chotai NR, Choksi DB, Damor S, Bhedi A. Intraperitoneal access by closed method (veress needle) versus open (Hasson's) method in laparoscopic surgery to create pneumoperitoneum. *International Surgery Journal* 2017; Vol 4 (8): 2786-2790.
 12. Pryor A, Bates AT. Abdominal access techniques used in laparoscopy UpToDate. 2018; 1-56.
 13. Noll E, Diemunsch S, Pottecher J, Rameaux J-P, Diana M, Sauleau E, et al. (2018) Prevention of laparoscopic surgery induced hypothermia with warmed humidified insufflation: Is the experimental combination of a warming blanket synergistic? *PLoS ONE* 2018; 13(7): e0199369. <https://doi.org/10.1371/journal.pone.0199369>
 14. Asfour V, Smythe E, Attia R. Vascular injury at laparoscopy: a guide to management. *J Obstet Gynaecol.* 2018 Jul;38(5):598-606. doi: 10.1080/01443615.2017.1410120.
 15. Mohammadi M, Shakiba B, Shirani M. Comparison of two methods of laparoscopic trocar insertion (Hasson and Visiport) in terms of speed and complication in urologic surgery. *Biomedicine (Taipei)*. 2018;8(4):22. doi:10.1051/bmdcn/2018080422
 16. Ahmad G, Baker J, Finnerty J, Phillips K, Watson A. Laparoscopic entry techniques. *Cochrane Database of Systematic Reviews* 2019, Issue 1. Art. No.: CD006583. DOI: 10.1002/14651858.CD006583.pub5.

DR. ASHOK KHURANA

M.B.B.S., M.D.

C-584, DEFENCE COLONY * NEW DELHI – 110024
Consultant in Reproductive Ultrasound

Routine Ultrasound * Interventional Procedures * Color Doppler
3D and 4D Ultrasound
Phone : 011-24336450, 24336390
Consultation By Appointment

- Appointments are available from 8.30 a.m. to 11.00 a.m. and 2.40 p.m. to 6.30 p.m. These need to be booked about 20 days in advance.
- Patients who urgently need a same day study are accommodated between 08.15 a.m. & 1.15 p.m. (Subject to a maximum of 15 patients). This involves considerable waiting, especially if there is no medical emergency.
- Emergencies should discuss on the phone when possible.
- The clinic is closed on Saturday & Sunday.
- Ovulation studies are done between 8.15 a.m. & 8.30 a.m.
- Telephone calls for appointments are attended to by the receptionists. This is from 8.30 a.m. to 6.00 p.m. only, from Monday to Saturday.
- No reports will be delivered after 6.30 p.m. and on Sundays.



Laparoscopic Ovarian Drilling

Malvika Sabharwal¹, Shivani Sabharwal², Nupur Chhabra², Swati Rai²

¹Director, ²Associate Consultants, Dept of Obst & Gynae, Jeewan Mala and Apollo Spectra Hospital, New Delhi

Introduction

Polycystic ovary syndrome (PCOS) is a frequent disorder, affecting approximately 5–10% of infertile women. It is responsible for more than 80% of cases of infertility due to anovulation.¹ A “stepwise approach” is followed for the management of infertility in patients with PCOS. Weight reduction & lifestyle management are first line of management. The first-line oral agents for ovulation induction (OI) are Letrozole (aromatase inhibitors) & clomiphene citrate (CC). Metformin (insulin sensitizers) is an adjunct to induction of ovulation in patients with glucose intolerance and obesity. Gonadotrophins are the second-line treatment in case of CC resistance or CC failure. LOD may be considered as a second-line treatment in a highly selected population.^{1,2}

The main indication for LOD is CC-resistant PCOS - as a second-line therapy for anovulatory infertile PCOS cases; specifically, as an alternative to gonadotropins.³⁻⁶ It is as effective as gonadotropins in terms of clinical pregnancy rates and live birth rates with the obvious advantages of spontaneous mono-ovulation thereby minimizing the need for intensive monitoring and eliminating the risks of ovarian hyperstimulation syndrome (OHSS) and multiple pregnancies.^{1,3-5} Royal College of Obstetricians and Gynecologists,⁷ American College of Obstetricians and Gynecologists,⁸ Society of Obstetricians and Gynecologists, Canada,⁹ and the recent PCOS consensus working group¹ - all recommend its use in highly selected cases, particularly in those with hypersecretion of luteinizing hormone (LH), normal body mass index, those needing laparoscopic assessment of the pelvis or who live too far away from the hospital for the intensive monitoring required during gonadotropin therapy. However, there are concerns regarding the long-term effects on ovarian function, especially iatrogenic adhesions and decreased ovarian reserve (DOR), which may potentially jeopardize future fertility. Despite its theoretical advantages, LOD is not superior to CC, neither as a first line therapy for OI^{3,5} nor for CC-failure or prior to *in vitro* fertilization (IVF).⁵ A recent Cochrane systematic review of 9 Randomized Controlled Trials (RCTs) and 16 trials concluded that there was no evidence of a significant difference in rates of clinical pregnancy (39.7 vs. 40.5%) or live birth (34 vs. 38%) in women with clomiphene-resistant PCOS undergoing LOD compared to other medical treatments.¹⁰ This implies that LOD is a valid, but not

the sole option for CC-resistant PCOS. The evidence for improvement in biochemical hyperandrogenism translating into comparable improvement in clinical hyperandrogenism is not clear; hence LOD should not be offered for non-fertility indications like amelioration of acne or hirsutism or for regularization of menstrual cycles.¹¹

Mechanism of Action

The most plausible mechanism of action is the destruction of ovarian follicles and a part of the ovarian stroma, inducing a reduction of serum androgens and inhibin levels, which results in an increase of Follicular Stimulating Hormone (FSH) and restores the ovulation function. LOD may also increase ovarian blood flow, allowing a high delivery of gonadotrophins and post-surgical local growth factors. An improvement of insulin sensitivity after LOD has also been suggested.^{2,10}

Surgical Techniques

Standardization of the surgical techniques is lacking. The common technique of LOD is the use of monopolar electrocautery (diathermy) or laser with comparable results.^{10,12,13,14} Normally, three to eight diathermy punctures are performed in each ovary using 600–800J energy for each puncture, leading to normal ovulation in 74% of the cases in the next 3–6months. Most surgeons perform four punctures per ovary, each for 4s at 40W (rule of 4), delivering 640J of energy per ovary (the lowest effective dose recommended). More than eight punctures seem to increase the occurrence of post-operative pelvic adhesions and decrease the ovarian reserve.¹⁰ Different modifications of the classic technique such as monopolar hook electrode & harmonic scalpel¹⁵ are available. Various transvaginal methods such as transvaginal hydrolaparoscopy (fertiloscopy)¹² and transvaginal sonography - guided ovarian interstitial laser treatment are also developed. However, larger prospective studies are needed to validate the use, safety, efficacy and long-term effects of these alternate techniques.

Clinical response is dose-dependent, with higher ovulation and pregnancy rates observed by increasing dose of thermal energy up to 600J/ovary, irrespective of ovarian volume.¹⁶ Conversely, adjusting thermal dose based on ovarian volume (60J/cc) has better

reproductive outcomes with similar postoperative adhesion rates than fixed dose of 600J/ovary.¹⁴ Despite lack of convincing evidence and significant reduction in operative time, most gynecologists still perform bilateral over unilateral drilling.^{10,17}

Benefit of Different Laparoscopic Ovarian Drilling Techniques

Today, there is no evidence that any one of the laparoscopic techniques should yield superior results. The studies are rather poor. Keckstein et al¹⁸ have treated 19 patients with the CO₂ laser and 11 patients with the Nd:YAG laser system in a non-randomised study. In a follow-up between 18 months and 30 months, eight pregnancies in the CO₂ laser group and three pregnancies after drilling with the Nd:YAG laser have been achieved (44% vs. 27%). Takeuchi et al¹⁵ compared ovarian drilling with a harmonic scalpel laser and a Nd:YAG laser in 17 patients per group. The endocrine profile after surgery was similar, the ovulation rate was 94% in both groups and the pregnancy rate within a follow-up of 2 years was 77% and 60%, respectively, without significant differences.

Additional Operative Procedures

Ovaries are cooled during the procedure by rinsing with Ringer's lactate¹⁹ or saline solution creating 500 ml artificial ascites. Some groups use hyaluronic acid gel as an adhesion barrier at the end of the procedure.²⁰ Greenblatt and Casper have used interceed to wrap one ovary in a comparative study.¹⁹

Laparoscopic Ovarian Surgery Versus Metformin

Two RCTs compared laparoscopic ovarian surgery to metformin and found that there was insufficient evidence to make a recommendation about laparoscopic ovarian surgery compared to metformin for live birth rate per patient, ovulation rate per cycle, pregnancy rate per cycle, pregnancy rate per patient, multiple pregnancies, miscarriage rate per pregnancy, adverse effects and quality of life^{20,21,22} largely because the evidence was conflicting.

Laparoscopic Ovarian Surgery Versus Clomiphene Citrate

Two RCTs compared laparoscopic ovarian surgery to clomiphene citrate^{23,24} and found that there was no difference between laparoscopic ovarian surgery and clomiphene citrate for live birth rate per patient and pregnancy rate per patient, ovulation rate per

patient and miscarriage rate per pregnancy. There was insufficient evidence to support or refute the use of laparoscopic ovarian surgery over clomiphene citrate for multiple pregnancies.

Laparoscopic Ovarian Surgery Versus Clomiphene Citrate + Metformin

Three RCTs compared laparoscopic ovarian surgery to clomiphene citrate plus metformin (all three studies reported in Farquhar 2012 systematic review)¹⁰ Meta-analyses found that clomiphene citrate plus metformin was better than laparoscopic ovarian surgery for live birth rate, but there was no difference for pregnancy rate per patient, multiple pregnancy rate, or miscarriage rate per pregnancy. There was insufficient evidence to support or refute the use of laparoscopic ovarian surgery over clomiphene citrate plus metformin for ovulation rate per patient, and OHSS.

Laparoscopic Ovarian Surgery Versus Aromatase Inhibitors

Three RCTs^{25,26,27} compared letrozole to laparoscopic ovarian surgery and found that there was insufficient evidence of a difference between letrozole and laparoscopic ovarian surgery.

Laparoscopic Ovarian Surgery Versus Aromatase Inhibitors + Metformin

One RCT compared laparoscopic ovarian surgery with letrozole plus metformin and found that there was insufficient evidence of a difference between the two interventions for ovulation, pregnancy and miscarriage rate per pregnancy.²⁸

Laparoscopic Ovarian Surgery Versus Gonadotrophins

One RCTs compared laparoscopic ovarian surgery to gonadotrophins and found that there was no difference between the interventions for live birth rate per patient and pregnancy rate per patient, ovulation rate per patient and miscarriage rate per pregnancy, but laparoscopic ovarian surgery was better than gonadotrophins for multiple pregnancy rate (OR 0.13 [0.03–0.59] $I^2 = 0\%$, four studies, 303 participants)¹⁰

Summary of Narrative Evidence

In a comprehensive review of ovarian drilling for PCOS, Fernandez⁶ concluded that ovarian drilling leads to spontaneous restoration of fertility in 20–64% of women with PCOS who had previously been infertile as

a result of anovulation and who did not respond to CC treatment, while the meta-analysis by Campo²⁹ reported a narrower range of success in 44–50% of patients. Several factors could influence the efficacy of ovarian drilling: a higher likelihood of success in patients with elevated LH concentrations (>10 IU/l) and <3 years of infertility. However, the influence of other factors, such as BMI, insulin resistance, and testosterone concentrations, is contradictory.³⁰ Multiple pregnancy rate varies from 0% to 10%, but is significantly lower than gonadotropins, thus making LOD an attractive option for CC-resistant PCOS.¹⁰ LOD does not seem to improve risk of Gestational Diabetes Mellitus (GDM), and higher incidence of GDM and pregnancy-induced hypertension have been reported after LOD.^{20,31,32,33} Several studies have reported that LOD prior to ART is beneficial in decreasing the risk of severe OHSS and increasing the “take home baby rate” in women who have previously had cancelled IVF cycles due to OHSS risk or who suffered from OHSS in a previous treatment. In conclusion, all meta-analysis confirmed that LOD is a second-line treatment in PCOS patients, especially those with CC resistance.¹⁰ The main benefits are shorter time to pregnancy and less need for ovulation induction drugs.

Complications

One of the main shortcomings of LOD is iatrogenic adhesions due to bleeding from the ovarian surface or premature contact between the ovary and the bowel after cauterization. Studies show a wide variation in adhesion rates^{34,17,35,36,37,38,19,39,40} involving higher risks with laser.^{34,37,39} Most studies reported mild to moderate adhesions which do not seem to affect pregnancy rates after LOD. Adhesion prevention strategies like liberal peritoneal lavage,⁴¹ application of adhesion barriers like intercede³⁹ and performance of adhesiolysis at early second-look laparoscopy,³⁷ are not effective in preventing *de novo* adhesions or in improving pregnancy rates.¹⁰ Ovary should be raised before application of energy and saline washed after the procedure to decrease the temperature thereby reducing the risk of injury.⁴² Another potential risk is Premature Ovarian Failure (POF), especially if the ovarian blood supply is damaged inadvertently or if large number of punctures are made, leading to excessive destruction of ovarian follicular pool or production of anti-ovarian antibodies.¹ Only one isolated case of ovarian atrophy following high-energy drilling (eight coagulation points at 400W for 5s) is reported.⁴³ When applied correctly, it does not appear to compromise the ovarian reserve. A prospective comparative study found that the extent of ovarian tissue damage was limited, ranging from

0.4% after four to 1% after eight coagulation punctures, each of 40W for 5s.⁴⁴ Coagulation should not be done within 8–10mm of the ovarian hilum.^{40,43} Unilateral drilling^{17,45} is associated with lesser risk of adhesions and decreased ovarian reserve but with equivalent reproductive outcomes.

What Next After Laparoscopic Ovarian Drilling Failure?

Laparoscopic ovarian drilling failure is defined as failure to ovulate within 6–8 weeks, recurrence of anovulatory status after an initial response or failure to conceive despite regular ovulation for 12 months.³ Since LOD improves responsiveness of the polycystic ovaries to subsequent OI agents, reintroduction of drug treatments (first CC and then gonadotropins) and possibly IVF can be considered in those who do not spontaneously become pregnant within 6 months after LOD once ovulation has been re-established or after 3 months when ovulation has not been detected.⁶

Re-Drilling — Should it Be Done?

The effectiveness of a second LOD, that is re-drilling in women with PCOS was investigated in a retrospective study comprising of 20 women who had undergone LOD 1–6 years prior.⁴⁶ Overall, ovulation and pregnancy rates were 60% and 53%, respectively, with better outcomes in LOD-sensitive than LOD-resistant cases (83 and 67% vs. 25 and 29%, respectively). However, there are concerns of adhesions and DOR, precluding the feasibility of a RCT to address this issue. Until then, repeated application of LOD should not be encouraged.¹

Conclusion

Laparoscopic ovarian drilling is an alternative approach to treat anovulatory polycystic ovary syndrome (PCOS) patients, although its indications are yet not well defined. The results are not superior to direct hormonal stimulation, but yield a lower multiple pregnancy rate and avoid the risk of ovarian hyperstimulation. Furthermore, laparoscopic ovarian drilling (LOD) normalises the hormonal environment, provides long-term effects and might improve the ovarian reaction to hormonal treatment. The need of a surgical approach and the formation of *de novo* adhesions is a major disadvantage of the method. Therefore, ovarian drilling must not be considered as the treatment of first choice. Patients with poor response to hormonal stimulation or disagreement with repeated multifollicular reaction to gonadotrophin stimulation might benefit from the surgical approach.

References

- Thessaloniki ESHRE/ASRM-Sponsored PCOS Consensus Workshop Group. Consensus on infertility treatment related to polycystic ovary syndrome. *Fertil Steril*. 2008;89:505–22.
- Berger JJ, Bates GW., Jr Optimal management of subfertility in polycystic ovary syndrome. *Int J Womens Health* (2014) 6:613–21.10.2147/IJWH.S48527
- Amer SA. Laparoscopic ovarian surgery for polycystic ovarian syndrome. In: Dunlop W, Ledger WL, editors. *Recent Advances in Obstetrics and Gynaecology*. 24th ed. London: Royal Society of Medicine Press Ltd; 2009. pp. 227–43.
- Flyckt RL, Goldberg JM. Laparoscopic ovarian drilling for clomiphene-resistant polycystic ovary syndrome. *Semin Reprod Med*. 2011;29:138–46.
- Abu Hashim H, Al-Inany H, De Vos M, Tournaye H. Three decades after Gjönnæss's laparoscopic ovarian drilling for treatment of PCOS; what do we know? An evidence-based approach. *Arch Gynecol Obstet*. 2013;288:409–22.
- Fernandez H, Morin-Surruca M, Torre A, Faivre E, Deffieux X, Gervaise A. Ovarian drilling for surgical treatment of polycystic ovarian syndrome: A comprehensive review. *Reprod Biomed Online*. 2011;22:556–68.
- Royal College of Obstetricians and Gynaecologists (RCOG). Longterm consequences of polycystic ovary syndrome. (Green-top Guideline; No. 33). London, (UK): Royal College of Obstetricians and Gynaecologists (RCOG) 2007:1–11.
- ACOG Committee on Practice Bulletins — Gynecology. ACOG Practice Bulletin No 108: Polycystic ovary syndrome. *Obstet Gynecol*. 2009;114:936–49.
- Vause TD, Cheung AP, Sierra S, Claman P, Graham J, Guillemin JA, et al. Ovulation induction in polycystic ovary syndrome: No 242, May 2010. *Int J Gynaecol Obstet*. 2010;111:95–100.
- Farquhar C, Brown J, Marjoribanks J. Laparoscopic drilling by diathermy or laser for ovulation induction in anovulatory polycystic ovary syndrome. *Cochrane Database Syst Rev*. 2012;6:CD001122.
- Johnson NP, Wang K. Is ovarian surgery effective for androgenic symptoms of polycystic ovarian syndrome? *J Obstet Gynaecol*. 2003;23:599–606.
- Poujade O, Gervaise A, Faivre E, Deffieux X, Fernandez H. Surgical management of infertility due to polycystic ovarian syndrome after failure of medical management. *Eur J Obstet Gynecol Reprod Biol* (2011) 158:242–7.10.1016/j.ejogrb.2011.05.007
- Sunj M, Canic T, Baldani DP, Tandara M, Jeroncic A, Palada I. Does unilateral laparoscopic diathermy adjusted to ovarian volume increase the chances of ovulation in women with polycystic ovary syndrome? *Hum Reprod* (2013) 28:2417–24.10.1093/humrep/det273
- Zakherah MS, Kamal MM, Hamed HO. Laparoscopic ovarian drilling in polycystic ovary syndrome: efficacy of adjusted thermal dose based on ovarian volume. *Fertil Steril* (2011) 95:1115–8.
- Takeuchi S, Futamura N, Takubo S, Noda N, Minoura H, Toyoda N. Polycystic ovary syndrome treated with laparoscopic ovarian drilling with a harmonic scalpel. A prospective, randomized study. *J Reprod Med*. 2002;47:816–20.
- Amer SA, Li TC, Cooke ID. A prospective dose-finding study of the amount of thermal energy required for laparoscopic ovarian diathermy. *Hum Reprod*. 2003;18:1693–8.
- Roy KK, Baruah J, Moda N, Kumar S. Evaluation of unilateral versus bilateral ovarian drilling in clomiphene citrate resistant cases of polycystic ovarian syndrome. *Arch Gynecol Obstet*. 2009;280:573–8.
- Keckstein G, Rossmann W, Spatzier K, Schneider V, Borschers K, Steiner R (1990) The effect of laparoscopic treatment of polycystic ovarian disease by CO₂ laser or Nd:YAG laser. *Surg Endosc* 4:103–107
- Greenblatt E, Casper R (1993) Adhesion formation after laparoscopic ovarian cautery for polycystic ovarian syndrome: lack of correlation with pregnancy rate. *Fertil Steril* 60:766–770
- Palomba S, Orio F, Nardo LG, Falbo A, Russo T, Corea D, Doldo P, Lombardi G, Tolino A, Colao A, Zullo F (2004) Metformin administration versus laparoscopic ovarian diathermy in clomiphene citrate-resistant women with polycystic ovary syndrome: a prospective parallel randomized double-blind placebo-controlled trial. *J Clin Endocrinol Metab* 89:4801–4809
- Palomba S, Orio FJ, Falbo A, Russo T, Tolino A, Zullo F. Plasminogen activator inhibitor 1 and miscarriage after metformin treatment and laparoscopic ovarian drilling in patients with polycystic ovary syndrome. *Fertil Steril* 2005; 3:761–765.
- Hamed H, Hasan A, Ahmed O, Ahmed M. Metformin versus laparoscopic ovarian drilling in clomiphene- and insulin-resistant women with polycystic ovary syndrome. *Int J Gynecol Obstet* 2010;108:143–147
- Amer S, Li T, Metwally M, Emarh M, Ledger W. Randomized controlled trial comparing laparoscopic ovarian diathermy with clomiphene citrate as a first-line method of ovulation induction in women with polycystic ovary syndrome. *Hum Reprod* 2009;1:219–225.
- Abu Hashim H, Wafa A, El Rakhawy M. Combined metformin and clomiphene citrate versus highly purified FSH for ovulation induction in clomiphene-resistant PCOS women: a randomised controlled trial. *Gynecol Endocrinol* 2011b;3:190–196
- Abu Hashim H, Mashaly AM, Badawy A. Letrozole versus laparoscopic ovarian diathermy for ovulation induction in clomiphene-resistant women with polycystic ovary syndrome: a randomized controlled trial. *Arch Gynecol Obstet* 2010; 5:567–571
- Abdellah MS. Reproductive outcome after letrozole versus laparoscopic ovarian drilling for clomiphene-resistant polycystic ovary syndrome. *Int J Gynaecol Obstet* 2011;3: 218–221
- Ibrahim MH, Tawfic M, Hassan MM, Sedky OH. Letrozole versus laparoscopic ovarian drilling in infertile women with PCOS resistant to clomiphene citrate. *Middle East Fertil Soc J* 2017;4:251–254
- Abd Elgafor I. Efficacy of combined metformin-

- letrozole in comparison with bilateral ovarian drilling in clomiphene-resistant infertile women with polycystic ovarian syndrome. *Arch Gynecol Obstet* 2013;1:119–123
29. Campo S. Ovulatory cycles, pregnancy outcome and complications after surgical treatment of polycystic ovary syndrome. *Obstet Gynecol Surv* (1998) 53:297–308.10.1097/00006254-199805000-00022
 30. van Wely M, Bayram N, van der Veen F, Bossuyt PM. Predictors for treatment failure after laparoscopic electrocautery of the ovaries in women with clomiphene citrate resistant polycystic ovary syndrome. *Hum Reprod* (2005) 20:900–5.10.1093/humrep/deh712
 31. Kriplani A, Manchanda R, Agarwal N, Nayar B. Laparoscopic ovarian drilling in clomiphene citrate-resistant women with polycystic ovary syndrome. *J Am Assoc Gynecol Laparosc*. 2001;8:511–8.
 32. Kong GW, Cheung LP, Lok IH. Effects of laparoscopic ovarian drilling in treating infertile anovulatory polycystic ovarian syndrome patients with and without metabolic syndrome. *Hong Kong Med J*. 2011;17:5–10.
 33. Al-Ojaimi EH. Pregnancy outcomes after laparoscopic ovarian drilling in women with polycystic ovarian syndrome. *Saudi Med J* 2006;27:519-25.
 34. Felemban A, Tan SL, Tulandi T. Laparoscopic treatment of polycystic ovaries with insulated needle cautery: A reappraisal. *Fertil Steril*. 2000;73:266–9.
 35. Kaya H, Sezik M, Ozkaya O. Evaluation of a new surgical approach for the treatment of clomiphene citrate-resistant infertility in polycystic ovary syndrome: Laparoscopic ovarian multi-needle intervention. *J Minim Invasive Gynecol*. 2005;12:355–8.
 36. Bayram N, van Wely M, Kaaijk EM, Bossuyt PM, van der Veen F. Using an electrocautery strategy or recombinant follicle stimulating hormone to induce ovulation in polycystic ovary syndrome: Randomised controlled trial. *BMJ*. 2004;328:192.
 37. Gurgan T, Urman B, Aksu T, Yarali H, Develioglu O, Kisinisci HA. The effect of short-interval laparoscopic lysis of adhesions on pregnancy rates following Nd-YAG laser photocoagulation of polycystic ovaries. *Obstet Gynecol*. 1992;80:45–7.
 38. Naether OG, Fischer R. Adhesion formation after laparoscopic electrocoagulation of the ovarian surface in polycystic ovary patients. *Fertil Steril*. 1993;60:95–8.
 39. Saravelos H, Li TC. Post-operative adhesions after laparoscopic electrosurgical treatment for polycystic ovarian syndrome with the application of Interceed to one ovary: A prospective randomized controlled study. *Hum Reprod*. 1996;11:992–7.
 40. Mercorio F, Mercorio A, Di Spiezio Sardo A, Barba GV, Pellicano M, Nappi C. Evaluation of ovarian adhesion formation after laparoscopic ovarian drilling by second-look minilaparoscopy. *Fertil Steril*. 2008;89:1229–33.
 41. Naether OG. Significant reduction of adnexal adhesions following laparoscopic electrocautery of the ovarian surface (LEOS) by lavage and artificial ascites. *Gynaecol Endosc*. 1995;4:17–19.
 42. Kaur M, Pranesh G, Mittal M, Gahlan A, Deepika K, Sashikala T, et al. Outcome of laparoscopic ovarian drilling in patients of clomiphene resistant polycystic ovary syndrome in a tertiary care center. *Int J Infertil Fetal Med*. 2013;4:39–44.
 43. Dabirashrafi H. Complications of laparoscopic ovarian cauterization. *Fertil Steril*. 1989;52:878–9.
 44. El-Sheikhah A, Aboulghar M, Read R, El-Hendawi E. The extent of ovarian damage produced by ovarian cauterisation in the human. *J Obstet Gynaecol*. 2004;24:664–6
 45. Kandil M, Selim M. Hormonal and sonographic assessment of ovarian reserve before and after laparoscopic ovarian drilling in polycystic ovary syndrome. *BJOG*. 2005;112: 1427–30.
 46. Amer SA, Li TC, Cooke ID. Repeated laparoscopic ovarian diathermy is effective in women with anovulatory infertility due to polycystic ovary syndrome. *Fertil Steril*. 2003;79:1211–5.

Laparoscopy in Endometriosis

Rakhi Rai¹, Kallol Kumar Roy², Vinod Nair¹, Vidushi Kulshrestha³

¹Fellow, MIGS, ²Professor and Head of MIGS Unit, ³Associate Professor, Department of Obstetrics & Gynaecology, AIIMS New Delhi

Introduction

Endometriosis is a chronic inflammatory disorder affecting reproductive aged women. It is found in 1-7% of women undergoing tubal sterilization, 9-50% of those evaluated for infertility by laparoscopy and 30-80% of women with pelvic pain. Around 30-50 % of women with endometriosis are infertile. Various events may lead to infertility in such patients which include inflammatory cytokines, impaired oocyte pick up & release, angiogenic factors, abnormally expressed genes, decreased ovarian reserve, poor oocyte or embryo quality or poor implantation. Endometriosis is always a clinical dilemma in terms of whether and how to treat it.

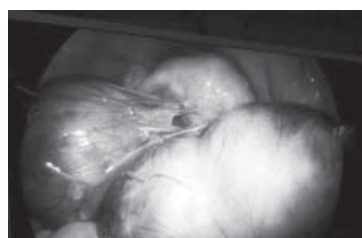

Fig. 1: Showing bilateral endometriomas

Endometriosis is found in 62% of adolescents who are undergoing laparoscopy for pain, 75% with chronic pelvic pain (CPP) resistant to treatment, 49% with CPP not resistant to treatment and 70% with dysmenorrhea. Both surgical and medical treatment are used in adolescents, although currently there is no consensus that whether surgery should be avoided or should be done as early as possible to prevent progression of disease. The major risk factors for endometriosis in adolescents include obstructive mullerian anomalies and early menarche.

Treatment of endometriosis is still debatable. The various options available for treatment include estrogen-progestin combination, progestins only, surgical management or combination of these. Although surgical treatment is the mainstay of treatment but is associated with inadvertent removal or destruction of normal ovarian tissue.

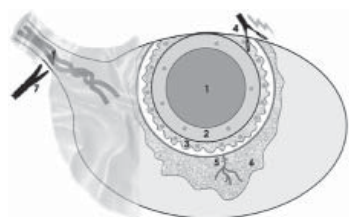


Fig 2: Follicular loss in surgery

- 1 Endometrioma
- 2 Pseudocapsule of endometrioma
- 3 Healthy cortex containing significant number of follicles stripped with pseudocapsule
- 4 Coagulation of vascular bed
- 5 Blood vessels injuries
- 6 Oedema/inflammation
- 7 Adhesiolysis and subsequent injuries of the blood vessels

Management of endometriosis is still a matter of debate. The treatment modality for endometriosis depends upon the clinical presentation like dysmenorrhea, chronic pelvic pain, infertility or features suggestive of DIE and final goal of the treatment. Medical management by suppressing ovulation is not effective in improving pregnancy rate for infertile patients. Adjunctive preoperative and postoperative hormonal treatment is not recommended in infertile patients. Surgical treatment or ART are the treatment strategies in such patients.

There are certain factors which determine the surgical treatment before undergoing IVF. The cyst size more than 4cm, symptoms like dysmenorrhea, features suggestive of malignancy on ultrasound, rapid growth and no previous surgery are the cases where surgical intervention is recommended. Most of ART specialists offer cystectomy to women who are not for IVF or for large endometriomas > 3cm who are for IVF. Surgery improves pain and fertility especially in those with severe endometriosis. It improves dyspareunia and response to IVF. If surgery is required, laparoscopy is the preferred route of treatment as it improves magnification, illumination and better visualization of disease.

According to ASRM 2012, there is insufficient evidence to suggest any benefit of laparoscopy in minimal or mild endometriosis to increase the chance of pregnancy. But if minimal or mild endometriosis is seen during laparoscopy done for any reason, ablation or excision of such visible lesions should be done. In stage I/II endometriosis associated infertility in young patients < 35 years, expectant management or superovulation with IUI (SO+IUI) can be considered but for women > 35 years, consider SO+IUI or IVF. Surgery doesn't help women with asymptomatic endometrioma prior to IVF and it doesn't improve success of IVF. But if endometrioma is > 4cm

size, surgery should be considered to confirm it histologically, improve ovarian response and better access for oocyte retrieval.

In women with stage III/IV endometriosis with infertility, conservative surgery is recommended as it has been seen that it improves fertility in such patients whereas in patients with previous surgery for endometriosis, IVF should be considered instead of repeat surgery.

According to recent publication by ESHRE (2019), do not do laparoscopy for detection & treatment of superficial peritoneal endometriosis in infertility patients in the absence of any pelvic symptom. Small endometriomas <4cm in size should not be removed with sole aim of improving fertility rates in patients planned for IVF. COS-IUI should not be done in endometriosis as it has been found to be of negligible value and exposes the women to increased chances of recurrence. Postoperative hormonal treatment with estrogen-progestins or progestins should always be recommended if patient is not planning conception. In adolescents with moderate to severe dysmenorrhea with clinical suspicion of early endometriosis, one should not jump to surgical management directly without prescribing prior medical therapy with progestins or estrogen-progestins.

Deep infiltrating endometriosis (DIE) is the presence of endometriotic nodules invading > 5mm into visceral or peritoneal surface. Such patients have non-specific chronic pelvic pain due to infiltration of subperitoneal or visceral nerves by implants along with prostaglandin and chemokine activation. There are two different schools of thought regarding management of DIE whether to go for surgery or not. Clinicians can consider surgical removal of deep endometriotic lesions as it will reduce pelvic pain and improve the quality of life (FOGSI 2017). In deep infiltrating endometriosis (DIE) involving bowel, spontaneous as well as ART pregnancy rates are improved postoperatively. As per ESHRE (2019), No attempt should be made to remove asymptomatic deep endometriosis and medically responsive symptomatic deep endometriosis. Surgical management of DIE is complex due to presence of fibrosis and adhesions at implant site. DIE mainly shows posterior involvement, uterosacral ligament being the most common site, in 83% of cases. Surgically, especially DIE include resection of uterosacral ligaments/peritoneum/anterior rectum/posterior vagina or intestine. Multidisciplinary team approach involving colorectal surgeon or urologist depending upon the

involvement is required. In case of isolated uterosacral ligament involvement, unilateral or bilateral excision can be done depending upon the position of nodules. If nodules are present on rectovaginal space, middle rectal artery shall be taken care of during dissection. Remove least amount of rectal serosa as far as possible. Once rectum is free, dissect nodule from vaginal wall if needed with resection of vaginal tissue. Pain free period of upto 24 months was seen following surgery as compared to expectant management in terms of dyspareunia (72.9% vs 48.2%), dysmenorrhea (38.9% vs 24.3%), dyschezia (70.1% vs 57.4%) in women with rectovaginal disease. Resection with reanastomosis is required in cases with involvement of sigmoid colon, multiple implants or bowel implants involving more than 50% of bowel circumference, > 3cm size or bowel stenosis. In case of isolated rectal involvement or implant, shaving or discoid resection shall be considered. Postoperative medical treatment in the form of OCPs or levonorgestrel IUS decreases the recurrence rate and improves pain relief.

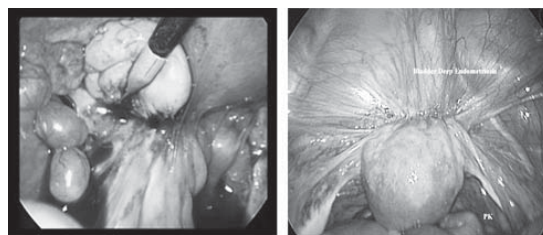


Fig 3: Deep Infiltrating Endometriosis

Surgical Techniques

Various surgical procedures for endometriosis are in place including transvaginal ultrasound guided cyst aspiration, cyst ablation, cystectomy and the more radical approach of salpingoophorectomy. The goals of surgical treatment are removal of all endometriotic implants, adhesiolysis, pain relief, reduced risk of recurrence & postoperative adhesions and restoration of normal anatomy and adhesion prevention.

There is a concern regarding further reduction in ovarian reserve with the surgery due to damage to healthy ovarian tissue. Various surgical techniques have been described so far for endometriosis which can be individualized depending upon treatment goal and various factors like age, main aim of management like infertility or to improve pain, location of endometrioma- unilateral or bilateral, ovarian reserve, extent of endometriosis and history any previous surgery. Laparoscopic cystectomy is the first choice for conservative management of endometriotic cysts. Results of ovarian cystectomy are conflicting especially in women undergoing IVF.

A number of studies have shown improved pregnancy rates following surgical management of endometriosis but certain studies showed no difference in pregnancy rates. Recently many studies have found negative effects of surgery on reproductive outcome by decreasing ovarian reserve. Hence there is a need to determine the best surgical technique for endometrioma preserving ovarian function.

Assess the extent of disease prior to surgery. It is the quality of surgery not the surgery per se which is more important in minimizing the ovarian trauma. Hence surgery by proper technique by expert specialist surgeons is the major determining factor.

Cystectomy (Stripping Technique)

Laparoscopic inspection of pelvis is done in a systematic way. Liver and diaphragm should be examined for any endometriotic implants. Inspect uterovesical fold and pouch of Douglas. After thorough inspection, ovaries should be made free by adhesiolysis. Try to handle the ovarian tissue atraumatically as much as possible. Mechanical dissection or hydrodissection are preferred methods for adhesiolysis as they are not associated with any thermal effect. Endometriotic capsule is usually densely adherent to ovarian parenchyma. Large endometriomas are usually adherent to ovarian fossa where they may also involve ureter, occasionally leading to ureteric obstruction. or posterior surface of uterus. Hence, it should be kept under consideration during surgery. During adhesiolysis usually endometrioma ruptures and chocolate material leaks into peritoneal cavity. Thorough irrigation suction should be done preferably with Ringer lactate solution then saline as it is protective against adhesion formation. Avoid excessive enlargement of opening and multiple incisions to prevent damage to functional ovarian tissue.

Make an incision over the thinnest part of the cyst to determine the plane of cleavage away from hilum or mesovarium or tubal fimbria on antimesenteric border. Hilum contains large intraovarian vessels. Hence surgeon should be careful while operating in this area as excessive bleeding may lead to damage to healthy ovarian tissue. Dilute vasopressin (0.1-1U/ml) can be inserted into the cyst wall to determine the cleavage plane as well as to reduce the bleeding. Using traction- countertraction technique with atraumatic grasping forceps, cyst wall is separated from ovarian parenchyma. Excessive force should be avoided as it may tear off normal ovarian tissue and may lead to excessive bleeding requiring coagulation, which may further reduce the ovarian reserve. Proper identification

of cleavage plane and coagulation at precise point are the keys to prevent damage to normal ovarian tissue. In case the cleavage plane is not identifiable after incision over cyst, then it is better to take a part of cyst for histological diagnosis and do ablation rather than causing ovarian damage by repeated attempts at cystectomy. Thorough irrigation should be done to check hemostasis and to remove any remnant cyst fluid. Bipolar coagulation at particular bleeding point needs to be done to prevent ovarian tissue damage. Monopolar coagulation should be avoided. Residual ovarian tissue is not sutured and is left for secondary healing. Sometimes ovarian reconstruction is required in large endometriomas. Sutures must be placed inside the ovary if suturing is required to prevent adhesion formation. In case of incomplete stripping of capsule is done, residual part must be treated by electrocoagulation/laser.

Ablation

Endometrioma is drained and cyst wall is destroyed with laser or plasma energy source. Power settings of 6-10 W or 30-55 W for CO₂ laser is usually used. Plasma energy is used in a coagulation mode at 10-40 at a distance of 5mm from tip of hand piece. The main goal is to vapourize the endometriotic cyst lining only till hemosiderin pigment stained tissue is no longer visible. The entire depth of cyst wall need not be vapourized as endometriotic tissue lies only superficially. Do intermittent irrigation to remove CO₂ debris and improve the visibility. It is done in cases of < 2cm endometriomas or endometrial implants. It has a high recurrence rate but it improves patient pain score and satisfaction rate.

Electrocoagulation

It involves coagulation of cyst lining with bipolar forceps at 25-40 w setting. Use small coagulation times to minimize thermal damage. Ovary should be cooled with irrigation fluid rapidly as depth of the tissue damage is more as compared to plasma energy or laser.

Combined Technique

During cystectomy, inadvertently removed normal ovarian tissue along with endometrioma contain primordial follicles, primary and secondary follicles in 69% cases whereas in 60% cases where ovarian tissue is removed from hilum contain no or only primordial follicles. Clear plane is usually difficult to obtain at ovarian hilum. Ho et al found that the

poor ovarian response is seen following ovarian hyperstimulation secondary to ovarian endometrioma surgery. Cystectomy leads to loss of normal ovarian tissue whereas ablation leads to incomplete removal and risk of recurrence. Hence, in order to overcome such problems, Donnez defined a new technique of modified combined cystectomy. In this technique, partial cystectomy (80-90%) of cyst is done by traction- countertraction method till it reaches the hilum followed by ablation of rest of cyst wall to prevent recurrence. At the hilum, cyst wall is most adherent and ovarian tissue is most functional resulting in loss of normal ovarian tissue. In this technique, heat doesn't spread to ovarian cortex/hilum, it only goes to capsule preventing recurrence. Hemostatic agents can be inserted to control bleeding from ovarian bed to prevent ovarian damage by heat.

In a study by Rawat et al (2019), two different techniques of laparoscopic cystectomy i.e. stripping vs cutting and coagulation at hilum were compared and found that decrease in ovarian reserve was less in cutting – coagulation at hilum group than stripping.

Two or Three Step Approach

It is used for large endometriomas. Firstly open and drain the endometrioma. Inspect the cyst cavity. Take a biopsy. Secondly, administer GnRh therapy for 3 months which leads to reduction in thickness of cyst wall and stromal vascularisation. Thirdly, second laparoscopy is done to complete surgery by either cystectomy or CO₂ vapourisation, plasma ablation or bipolar diathermy of cyst lining. This procedure helps in reducing the risk of recurrence and damage to ovarian tissue.

Systematic review found that cystectomy is superior than ablation in terms of reduction in pain, recurrence rate and spontaneous pregnancy rate.

The type of hemostatic method following cystectomy also has an effect on AMH. Hemostatic sealant has no effect on AMH. Bipolar causes more reduction in AMH than suturing. In a study by Li C Z, AMH levels were compared amongst women with endometriosis using different hemostatic modalities and found that bipolar and harmonic scalpel result in reduction of ovarian reserve whereas suturing is superior. Rate of recurrence after ablation varies from 2-50% in 2 years but can be as low as 0% at 2 years depending upon optimal excision.

Laparoscopic uterine nerve ablation (LUNA) and laparoscopic presacral neurectomy (LPSN) are the adjunctive procedures to enhance pain relief. LUNA

causes disruption of efferent nerve fibres in uterosacral ligaments thereby decreasing dysmenorrhea. LPSN interrupts superior hypogastric plexus i.e. symptomatic innervation to uterus. Cochrane review didn't find any short-term pain relief. One large RCT didn't demonstrate any difference in patients having recurrent dysmenorrhea in laparoscopic surgery with LUNA group vs conservative laparoscopic surgery group. LPSN had some benefit of improving long term mid abdominal pain only but at the same time, it is more technically challenging procedure with high chances of bleeding due to injury to surrounding venous plexus, hence lot of expertise is required.

Conclusion

To conclude, as there is no consensus on appropriate management of endometriosis, debates are ongoing regarding risks and benefits of laparoscopy in endometriosis. Small endometriomas <4cm in size should not be removed with sole aim of improving fertility rates in patients planned for IVF. No attempt should be made to remove asymptomatic deep endometriosis and medically responsive symptomatic deep endometriosis.

Suggested Reading

1. Benaglia L, Somigliana E, Vighi V, Ragni G, Vercellini P, Fedele L. Rate of severe ovarian damage following surgery for endometriomas. *Human Reproduction*. 2010; 25 (3): 678–682.
2. Roy KK, Singla S, Chawla H, Baruah J, Sharma JB, Jain S. A Randomized Control Trial Comparing Direct Stripping and Bipolar Electrocoagulation for Laparoscopic Endometriotic Cystectomy-Surgical and Histopathological Aspects. *International Journal of Clinical Medicine* 2011; 2: 69-74.
3. Muzii L, Miller CE. The singer, not the song. *J Minim Invasive Gynecol*. 2011 Sep-Oct;18(5):666-7. doi: 10.1016/j.jmig.2011.06.016.
4. Armstrong C. ACOG Updates Guideline on Diagnosis and Treatment of Endometriosis. *Am Fam Physician*. 2011 Jan 1;83(1):84-85.
5. Practice Committee. *Endometriosis and infertility: A Committee Opinion*. *Fertil Steril* 2012 ;98 (3): 591–598
6. Unlu C, Yildirim G. Ovarian cystectomy in endometriomas: Combined approach. *J Turk Ger Gynecol Assoc* 2014; 15: 177-89.
7. Dunselman GAJ, Vermeulen N, Becker C, Calhaz-Jorge C, D'Hooghe T, De Bie B, Heikinheimo O, Horne AW, Kiesel L, Nap A, Prentice A, Saridogan E, Soriano D, Nelen W. ESHRE guideline: management of women with endometriosis, *Human Reproduction*, Volume 29, Issue 3, March 2014, Pages 400–412, <https://doi.org/10.1093/humrep/det457>.

8. Yeung P. The Laparoscopic Management of Endometriosis in Patients with Pelvic Pain. *Obstet Gynecol Clin N Am* 2014; 41: 371–383.
9. Brown J, Farquhar C. Endometriosis: an overview of Cochrane Reviews. *Cochrane Database of Systematic Reviews* 2014, Issue 3. Art. No.: CD009590. DOI: 10.1002/14651858.CD009590.
10. Muzii L, Achilli C, Lecce F, Bianchi A, Franceschetti S, Marchetti C, Perniola G, Panici PB. Second surgery for recurrent endometriomas is more harmful to healthy ovarian tissue and ovarian reserve than first surgery. *Fertil Steril*. 2015 Mar;103(3):738-43. doi: 10.1016/j.fertnstert.2014.12.101.
11. Carrillo L, Seidman DS, Cittadini E, Meirow D. The role of fertility preservation in patients with endometriosis. *J Assist Reprod Genet*. 2016 Mar;33(3):317-323. doi: 10.1007/s10815-016-0646-z. Epub 2016 Jan 14.
12. Parasar P, Ozcan P, Terry KL. Endometriosis: Epidemiology, Diagnosis and Clinical Management. *Curr Obstet Gynecol Rep*. 2017 Mar; 6(1): 34–41.
13. Working group of ESGE, ESHRE and WES, Ertan Saridogan, Christian M Becker, Anis Feki, Grigoris F Grimbizis, Lone Hummelshoj, Joerg Keckstein, Michelle Nisolle, Vasilios Tanos, Uwe A Ulrich, Nathalie Vermeulen, Rudy Leon De Wilde, Recommendations for the Surgical Treatment of Endometriosis. Part 1: Ovarian Endometrioma, *Human Reproduction Open*, Volume 2017, Issue 4, 2017, hox016, <https://doi.org/10.1093/hropen/hox016>
14. Zanelotti A, DeCherney AH. Surgery and Endometriosis. *Clin Obstet Gynecol*. 2017; 60(3): 477–484. doi:10.1097/GRF.0000000000000291
15. Jayaprakasan K, Becker C, Mittal M on behalf of the Royal College of Obstetricians and Gynaecologists. The Effect of Surgery for Endometriomas on Fertility. *Scientific Impact Paper No. 55. BJOG* 2017;125:e19–e28.
16. Cranney R, Condous G, Reid S. An update on the diagnosis, surgical management, and fertility outcomes for women with endometrioma. *Acta Obstet Gynecol Scand* 2017; 96:633–643.
17. Good Clinical Practice Recommendations on Endometriosis 2017.
18. Roman H. Endometriosis surgery and preservation of fertility, what surgeons should know. *J. of Visceral Surgery* 2018; 155S: S31-36.
19. Hwang H, Chung YJ, Lee SR, Park HT, Song JY, Kim H, Lee DY, Lee EJ, Kim M, Tack Oh S. Clinical evaluation and management of endometriosis: guideline for Korean patients from Korean Society of Endometriosis. *Obstet Gynecol Sci*. 2018 Sep; 61(5): 553–564.
20. Daniilidis A, Pados G. Comments on the ESHRE recommendations for the treatment of minimal endometriosis in infertile women. *Reprod Biomed Online*. 2018 Jan; 36(1):84-87. doi: 10.1016/j.rbmo.2017.10.103.
21. Falcone T, Wilson JR. Surgical Treatment of Endometriosis: Excision Versus Ablation of Peritoneal Disease. *Journal of Minimally Invasive Gynecology*, 2019; 26(1): 1-2.
22. Rawat S, Roy KK, Kumar S, Sharma JB, Singh N, Chodsol K. A randomised comparative study of ovarian reserve following two different techniques of laparoscopic cystectomy in ovarian endometrioma. *International Journal of Clinical Obstetrics and Gynaecology* 2019; 3(1): 230-237.
23. When more is not better: 10 ‘don’ts’ in endometriosis management. An *ETIC* position statement. *Human Reproduction Open* 2019; 3, 1-15 doi.org/10.1093/hropen/hoz009.

Calendar of Monthly Clinical Meetings 2019-20

Months	Name of the Institute
25 th October, 2019	ESI Hospital
29 th November, 2019	MAMC & LN Hospital
27 th December, 2019	Sir Ganga Ram Hospital
31 st January, 2020	Dr RML Hospital
28 th February, 2020	UCMS & GTB Hospital
27 th March, 2020	LHMC
24 th April, 2020	Apollo Hospital



Royal College of Obstetricians & Gynaecologists **AICC Northern Zone India**

Website: www.aicccognzindia.com

Chairperson: Dr Nirmala Agarwal: (n.menoky@gmail.com / 9811888732)

Vice Chairperson
Dr Anita Kaul

Hon. Secretary
Dr Arbinder Dang

RCOG UK MRCOG Final Preparation: Part II Course

Friday 3rd, Saturday 4th Sunday 5th January 2020 (Total 3 Days)

Limited to 40 candidates only (First Come First Serve basis)

Overview

In March 2015 the MRCOG Part 2 Written exam changed its format. The two written papers now consist of Single Best Answer Questions (SBAs) and Extended Matching Questions (EMQs). The course focuses on polishing your exam techniques to improve your chances of passing the NEW written papers.

Developed and taught by experienced MRCOG Examiners, you will have tutorials about the new exam question formats and ample opportunity to practice SBAs and EMQs. This course will map the RCOG core curriculum and the examination syllabus; you will also have lectures from experts about current developments and hot topics in key curriculum area.

We recommend you book early to avoid disappointment. There are a maximum of 40 places.

Who should attend?

- Candidates sitting the 2020 Part 2 MRCOG Examination

After completing this course, you will be able to:

- Gain familiarity with the new format of the part 2 MRCOG written papers
- Understand the standard of the required knowledge
- Understand core O&G topics in relation to UK practice
- Understand training within the NHS

Course Fee: Rs 35,000

Venue - Sant Parmanand Hospital
18 Sham Nath Marg, Civil Lines, Delhi- 110054

UK Course Organizer & Convener -

Dr Shantanu Acharya (UK)

India Conveners and Contacts for details -

Dr Nirmala Agarwal (n.menoky@gmail.com / 9811888732)

Dr Arbinder Dang (arbidang@gmail.com / 9871356917)

Dr Sweta Gupta (swetagupta06@yahoo.com / 8130140007)

Dr Shelly Arora (drshellyaroramamc@gmail.com / 9971725369)

**For Accommodation, Hotel Bookings, Travel Enquiry Contact Miss Carolina Fernandez Cox & Kings +919711992043/
Carolina.fernandes@cox&kings.com**

Certificate of attendance for this course will be provided by the RCOG UK

Registration Guidelines (Online registration available on website)

- Registration form to be downloaded from website www.aicccognzindia.com
- Bank Transfer or Demand Draft must be made in favour of "Royal College of Obstetricians and Gynaecologists NZ India" payable at New Delhi. (Cheques not accepted).
- There will be no refunds on cancellation.
- Registration request along with Demand Draft to be posted to the Secretariat mailing address as given below:-

Mailing Address:

RCOG North Zone Secretariat

OT Complex 3rd Floor Sant Parmanand Hospital, 18 Shamnath Marg, Civil Lines, Delhi 110054

Mr Asif Muniri (Administrative Assistant) +919560069925 / 9716801190, Tel No - 91-11-23981260, 23994401-10 Ext 314

Email: rcognz2017@gmail.com / n.menoky@gmail.com / arbidang@gmail.com

Association of Obstetricians & Gynaecologists of Delhi

MEMBERSHIP FORM

Name:.....

Surname:

Qualification:.....

Postal Address:

City:..... State: Pin code:.....

Place of Working:.....

Residence Ph. No. Clinical / Hospital Ph. No.

Mobile No:..... Email:.....

Gender: Male:..... Female:.....

Date of Birth: Date..... Month Year.....

Member of Any Society:.....

Proposed by

Cheque/DD / No:

Enclosed: Cheque/Demand Draft should be drawn in favour of:

For Life Membership : Rs. 11,000 + Rs. 1,980 (18% GST applicable) = Rs. 12,980

For New Annual Membership* : Rs. 2,000 + Rs. 360 (18% GST applicable) = Rs. 2,360

For Old Renewal Membership+ : Rs. 1,200 + Rs. 216 (18% GST applicable) = Rs. 1,416

Encl.: Attach Two Photocopies of All Degrees, DMC Certificate and Two Photographs

***-Annual Membership is for the calendar year January to December.**

+ - In case of renewal, mention old membership number.

Note: 18% GST will be applicable as FOGSI requires it.

Send Complete Membership Form Along With Cheque / DD and Photocopy of required documents.

AOGD Secretariat

Department of Obstetrics and Gynecology,
3076, Teaching Block, IIIrd Floor, All India Institute of Medical Sciences, Ansari Nagar, New Delhi-110029
www.aogd.org. Email: secretaryaogd2019@gmail.com

41st Annual Conference AOGD

28th - 29th September 2019

Prize Winners

Category	Award	Name	Institute	Topic
Research Paper- Best Competition Paper	Gold Medal	Dr Garima Patel	AIIMS	To Evaluate the Pre-Operative Serum Levels of Human Epididymis Protein (HE-4) and Cancer Antigen 125 (CA-125) in Women with Endometrial Cancer
	Silver Medal	Dr Chhavi Gupta	VMMC & SJH	Carle's Obstetric Early Warning Score as A Screening Tool for Obstetric Critical Care Admission
	Bronze Medal	Dr Nuzhat Zaman	MAMC	Comparison of Dydrogesterone- Human Menopausal Gonadotropin Protocol with the Antagonist Protocol in Prevention of Premature LH Surge and IVF Outcomes in In Vitro Fertilization Cycles with Frozen Embryo Transfer
Dr Neera Agarwal's Medal for Best paper on theme topic of Obstetrics (Maternal Health)	Gold Medal	Dr Minal Soni	Artemis Hospital	Efficacy of Fetal Renal Volume & its Doppler Flow in Prediction of Intra Uterine Growth Retardation
Dr Suneeta Mittal's Medal on Population Stabilization	Gold Medal	Dr Megha Gupta	VMMC & SJH	Comparison of Cencroman and PPIUCD in Terms of Safty, Aceptability and Continuation Rate in Immediate Postpartum Period
Dr U.P Jha & Raj Soni's Medal on best paper presentation in Endoscopy	Gold Medal	Dr Aruna Nigam	HIMSR, Jamia Hamdard	Outcome of Conservative Laparoscopic Approach for Children and Adolescent Ovarian Torsion: Cohort study
Dr U.P Jha & Dewan Balakram's Medal on best presentation on Gynae Oncology	Gold Medal	Dr Shubham Bidhuri	VMMC & SJH	Study of 9 Types of HPV Strains Covered in Nonavalent Vaccine in Cervical Samples of Women Older than 30yrs of Age.
Mr S. Bhattacharya & Dr Ganguli's Medal Free Paper (Miscellaneous Category)	Gold Medal	Dr Vijaya Bharathi K	AIIMS	Diagnosis of Occult SUI
	Silver Medal	Dr Utkarsha Aggarwal	ESI – Basai Dharapur	Fetal Weight Estimation Models Using Umbilical cord Thickness and Fetal Limb Volume and its comparison with the Conventional methods of Ultrasound
Poster Presentation	Gold Medal	Dr Sumedha Sharma	HIMSR, Jamia Hamdard	Outcome of Conservative Laparoscopic Approach for Children and Adolescent Ovarian Torsion: Cohort study
	Gold Medal	Dr Mohini Sachdeva		Endometrium in Women with Recurrent and Luteal Phase Defect in Women with Recurrent Pregnancy Loss
	Silver Medal	Dr Sneha Mishra	MAMC	Outcome of Expectantly Managed Small for Gestational Age Pregnancies with Normal Doppler Parameters – A prospective cohort study
	Silver Medal	Dr Karthiga RG	MAMC	A Case Report of Intravenous Leiomyomatosis Extending into the Right Atrium
Slogan	First Prize	Dr Yukti Bhardwaj	BPS, GMC, Sonapat	
	Second Prize	Dr Neha Gupta	HIMSR	
Dr Batra's Medal winning team of AOGD Quiz	Gold Medal	Dr Garima Patel, Dr Sathiya Priya	AIIMS	
	Silver Medal	Dr Sneha Mishra, Dr Ishita Aggarwal	MAMC	
Dr S N Mukherjee Rotating Trophy	Best AOGD Monthly Clinical Meeting		UCMS	

AOGD Office-Bearers 2019-20



Dr Sunesh Kumar
President



Dr Ashok Kumar
Vice President



Dr Vatsla Dadhwal
Hon. Secretary



Dr K Aparna Sharma
Joint Secretary



Dr Rohini Sehgal
Treasurer



Dr Dipika Deka



Dr Neerja Bhatla



Dr K K Roy



Dr Neena Malhotra

Scientific Advisors

Editorial Board



Dr J B Sharma
Editor



Dr Reeta Mahey



Dr Vanamail



Dr Juhi Bharti
Web Editor

Co-Editors



Dr Neeta Singh



Dr Garima Kachhawa



Dr Seema Singhal



Dr Jyoti Meena



Dr Vidushi Kulshreshtha



Dr Rajesh Kumari

Scientific Committee

Clinical Secretaries

Events Held

- Monthly Clinical Meeting on 30th August, 2019 at Army hospital – R & R



- AOGD Reproductive Endocrinology Committee in association with DGF South-West & DGF- West conducted a CME on Infertility & Role of Estrogen in thin Endometrium on 31st August, 2019 at Radisson Blue, Dwarka. Thanks to Dr Priya Dahiya for making us a part..!



- DGES Conference on 31st August & 1st September, 2019 at Hotel Jaypee Sidhartha, New Delhi under the aegis of AOGD



- CME on " Surgical Wounds" on 7th September, 2019 at GTB Hospital organized by Dr A G Radhika under the aegis of AOGD



- Simm Black Travelling fellowship Oration on 9th September, 2019 organized by AIIMS



- Pre-Conference workshops on "1st Trimester USG-Quality control" on 26th September, 2019 at Lady Harding Medical College



- Pre-Conference workshops on "Urogynaecology" on 26th September, 2019 at AIIMS



- Pre-Conference workshops on "Ovulation Induction and IUI" on 26th September, 2019 at Max Hospital



- Pre-Conference workshops on "Preventive Oncology" on 26th September, 2019 at Safdarjung Hospital



- Pre-Conference Workshops on “Endometriosis (Video Workshop)” on 27th September, 2019 at India Habitat centre



- Pre-Conference workshops on “Obstetrics skills” on 27th September, 2019 at HIMsr Hospital



- Pre-Conference workshops on “Endoscopy” on 27th September, 2019 at GTB Hospital, New Delhi



- Pre-Conference workshops on “Saving Mothers” on 27th September, 2019 at Sir Ganga Ram Hospital, New Delhi



- Pre-Conference workshops on “Medico-Legal Aspects in Obs & Gynae” on 27th September, 2019 at MAMC.



- 41st Annual Conference of AOGD on 28th & 29th September, 2019 at Eros Hotel Organize by Dept. of Obs & Gynae, AIIMS, New Delhi.







- Cultural Event on 28th September, 2019 at Eros Hotel.



- Walkathon on 29th September, 2019 at Nehru Place Market



Specimen Retrieval in MIGS

Vinod Nair¹, Garima Kachhawa², Rakhi Rai¹, Archana Minz³

¹Fellow, MIGS, ²Addl Professor, ³Senior Resident, Dept of Obst & Gynae, AIIMS New Delhi

Introduction

Along with advances in technology and its extended application fields, minimally invasive surgery brought an inherent challenge, the safe extraction of specimen. Advanced surgical techniques improved our ability as minimally invasive surgeons and also brought serious risks and litigations. Specimen extraction has always been a problem in minimally invasive approach. There are certain known challenges pertaining to specimen extraction in minimally invasive surgery. Increase in operative time is the most common disadvantage. At times, the time taken for specimen extraction is more than the time taken for the surgery itself. Spillage of contents and dissemination of tissue are other serious concerns. Even though rare, port site metastasis, port wound hernia and injury to viscera are all reported problems associated with specimen extraction.

Various factors influence the method of specimen extraction. As the size of the specimen increases, the difficulty in bringing it out of the abdomen also increases. Consistency of the specimen, whether solid or cystic also greatly influences its extraction. And what if malignancy is suspected? We will discuss this aspect in detail subsequently. Another important factor here is experience of the surgeon. Depending on all these factors, the operating surgeon can choose from an array of tissue extraction methods as discussed below.

Port Site Extraction

Port Site Extraction is the most commonly practised specimen retrieval technique in MIGS. It is the easiest to practice and is the most effective method in retrieving a salpingectomy specimen or a small ovarian cyst. However, in case of large and solid specimens, this method becomes ineffective. Usually, left lower port is selected for specimen extraction. Most of the times, the 5mm port is expanded with a Kelly's forceps and specimen extracted directly with the forceps itself. Another method is to replace the 5mm port with a 10mm one, insert a 10mm grasper and retrieve the specimen. Another method is to insert a 5mm scope through one of the side ports and extract the specimen with a 10mm grasper through the central port. This method prevents the need of expanding a 5mm port.

Increased post op pain and discomfort have been reported by most of the patients who have undergone specimen retrieval through port expansion. Injury to anterior abdominal wall vessels resulting in bleeding and local haematoma formation have also been reported as an associated complication with port site specimen retrieval.

Spillage of contents of dermoid cysts often causes serious complications such as chemical peritonitis, significant pelvic adhesions, enterocutaneous fistula, bowel obstruction, abdominal wall abscess, chronic granulomatous peritonitis etc. which may require re-intervention either medically or surgically. Compared to laparotomy, there is a significantly increased chance of spillage of contents in laparoscopy (4-13% in laparotomy Vs 15-100% in laparoscopy) especially during extraction of specimen. Using an endobag during dissection and extraction of specimen can minimize the risk of spillage. If spillage occurs, thorough lavage of the peritoneal cavity with 5-10 litre of Normal Saline is recommended. Irrigation with 10% Dextrose in water (D10W) is recommended in case of a ruptured Mucinous Cystadenoma, in an effort to remove the thick, tenacious mucus and to prevent its reaccumulation.

Port site metastasis is a rare occurrence with an incidence of 0.3 - 1%. Direct wound implantation while extraction of specimen through the port site is an important causative factor. Direct implantation by frequent changes of laparoscopic instruments and spread of tumour cells due to 'chimney effect' of CO2 pneumoperitoneum itself are other proposed theories of port site metastasis. Keeping a low intra abdominal pressure of < 12 mm of Hg, deflation with trocar in place, trocar site irrigation and suturing of peritoneum and fascia at the port sites are various techniques employed for reducing port site implantation of tumour cells.

Port site hernia, again a rare phenomenon (incidence of 0.3 - 0.9%), has been reported in those ports through which tissue extraction was done. Most port site hernias occur in the 10mm port either umbilical or supra-umbilical mid-line ports. Closure of rectus sheath is recommended in any port which is more than 7mm in size, in immunocompromised patients and in ports through which specimen has been extracted.

Minilaparotomy

Minilaparotomy is a well known and relatively easy method of specimen extraction. The location of minilaparotomy incision for laparoscopic specimen extraction can be suprapubic, umbilical or at one of the port sites. There are various circumferential self retaining retractors available to aid the specimen extraction such as Alexis, Surgisleeve, Mobius etc. However, how big or how small the incision should be to call it a minilaparotomy is not defined. The purpose of minimally invasive surgery would be partially lost if a laparotomy has to be done for extracting the specimen. Cosmetic concerns of the patient also add to it. However, there are certain advantages of this hybrid method of combining laparoscopy and minilaparotomy. Often, a diagnostic laparoscopy is done first for thorough inspection of the peritoneal cavity to rule out any feature of unrecognized malignancy and to determine the location and extent of minilaparotomy incision. This method has proven to take shorter operative time and reduced intraperitoneal spillage.

Colpotomy

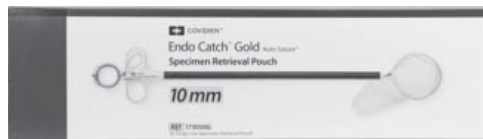Posterior colpotomy was documented many years ago. It is a safe and easily learnt procedure. Either traditional colpotomy with a scalpel as we open the posterior pouch in vaginal hysterectomy or with trocar insertion under laparoscopic vision can be done. Care should be taken to avoid injuring rectum. Often, a sponge stick or vaginal probe is placed in the posterior fornix to cause a bulge which can act as a guide while making the posterior colpotomy incision laparoscopically using an energy source or scissors. Care should be taken to remain medial to the uterosacral ligaments. After extraction of specimen, the incision should be examined for extensions and haematoma formation and closed either laparoscopically or vaginally using absorbable sutures.

Large sized solid as well as cystic masses can be extracted through colpotomy. However, colpotomy becomes technically difficult in nulliparous women and in those with fixed retroverted uterus and frozen pelvis. Injury to surrounding structures, especially rectum is a concern. Moreover, close proximity of bowel loops in pouch of Douglas makes morcellation and specimen extraction technically difficult.

Specimen Retrieval Bags

Specimen retrieval bags, more commonly known as 'Endobags' are used in laparoscopic specimen extraction to avoid spillage and contamination. There

are many varieties of commercially made bags and homemade 'Glovebags' as well.



Pic 1: *Commercially available specimen retrieval bag*



Pic 2: *'Glove bag' for specimen retrieval*

Morcellation

Morcellation involves cutting a large specimen into smaller pieces so as to enable its extraction. This can be achieved either manually or by electromechanical morcellation. There are three kinds of morcellation in practice; (1) vaginal morcellation with a scalpel through colpotomy/culdotomy, (2) minilaparotomy/laparoendoscopic single site (LESS) morcellation with a scalpel and (3) electromechanical morcellation (EMM). First manual morcellation was reported by Semm in 1991 closely followed by demonstration of electromechanical morcellation by Steiner in 1993.

Electromechanical morcellation works with the principle of cutting, peeling or dividing the tissue using energy. Usually a 12 - 20 mm diameter port or incision is required for most of the commercially available electromechanical morcellators. Depending on blade diameter, weight, cutting speed, morcellation rate and mechanism of action, various types of morcellators are available. Those morcellators which use 'peeling' technique perform faster as compared to others. Advanced morcellators can do tissue morcellation at the rate of around 40-50g per minute.

Preoperative evaluation has an important role when power morcellation is being considered. Any gynaecological malignancy should be ruled out prior to contemplating electromechanical morcellation. Uterine Sarcomas have a higher incidence of recurrence and poor prognosis even in early stages with a 5 year survival rate of around 40%. Other uterine cancers comparatively thrive better even after morcellation. Even though it is possible to rule out most of the malignancies during pre-operative evaluation, rare varieties such as leiomyosarcoma

may mimic benign conditions like uterine leiomyoma. Hence, both the surgeon and the patient considering power morcellation as an option during gynecologic surgery should discuss the risks, benefits, and suitable alternatives.


There should be a strong suspicion of uterine sarcoma in a postmenopausal patient who is undergoing hysterectomy especially after 60 years of age. It has been found that leiomyosarcomas are comparatively more common in black race. Prolonged Tamoxifen use of over 5 years and a past history of pelvic irradiation are other risk factors. Hereditary Leiomyomatosis and Renal Cell Carcinoma (HLRCC) Syndrome and survivors of childhood Retinoblastoma are more prone to uterine sarcomas. A rapid growth of the tumour, even-though a non-reliable indicator, should be evaluated further to rule out the possibility of sarcoma before proceeding with surgery.

Imaging plays an important role in the preoperative evaluation of uterine fibroids. There are certain features in radiological imaging which are suggestive of leiomyosarcoma. A heterogenous mass with central necrosis on ultrasonography and doppler velocimetry features of low tumour blood flow resistance index (RI) and high peak systolic velocity are the usual picture of leiomyosarcoma. Computed Tomography (CT) scan also demonstrates a heterogenous mass with central low attenuation suggestive of necrosis. Magnetic Resonance Imaging (MRI) features such as large size, tissue signal heterogeneity, central necrosis, ill-defined margins etc. are features suggestive of malignancy as well as a degenerating fibroid. Dynamic contrast enhanced MRI with a Gadolinium based contrast (Gadopentetate dimeglumine) agent (Gd-DTPA) shows an enhanced uptake in one minute film in case of Leiomyosarcoma which can be differentiated from a degenerating fibroid. This particular imaging modality is promising but is quite expensive and available only in specialised centres.

Lactate Dehydrogenase (LDH) and more specifically LDH Isoenzyme 3 is elevated in Leiomyosarcoma. A protocol that used Gd-DTPA MRI combined with serum analysis of LDH Isoenzyme -3 showed 100% specificity, 100% positive & negative predictive values and 100% diagnostic accuracy. However, these results have not been duplicated, nor do they address non- degenerating fibroids. CA 125 is raised only in advanced stage disease and hence, is not a reliable choice of chemical marker for leiomyosarcoma.

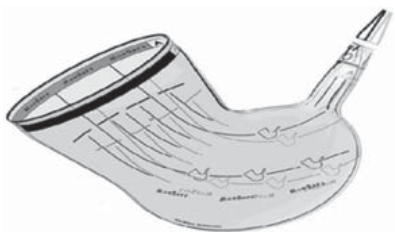
To prevent the spread of benign as well as malignant tissues during morcellation, a new method was

invented known as contained or in-bag morcellation. Several methods and many types of bags are in use. The first of its kind was demonstrated by Einarsson et al in 2014 known as Sydney in-bag morcellation. In this technique, an Endocatch bag or Anchor tissue retrieval system is used. Drawback of this technique is that there can be spillage of tissue through the pierced portion of the bag. Another such bag is Lahey bag which works with similar technique. Pneumoliner is a US-FDA approved bag for contained morcellation.



Pic 4: Pneumoliner bag for contained morcellation.

Morsafe bag is available in the Indian market which eliminates the requirement of puncturing the bag and thereby preventing the possibility of spillage and makes contained morcellation possible in multiport laparoscopy. This bag is available in small, medium and large sizes.



Pic 5: Morsafe bag for contained morcellation

There is a significant learning curve involved in contained morcellation and advanced laparoscopic skills are required to avoid complications. Variability in size, shape and weight of uterine tissue makes placement of specimen into the bag challenging. Puncturing the bag in some cases of multiport laparoscopy can be at risk of spillage of tumour cells. Visualisation of the mass within the bag as well as vital structures external to the bag may be sub-optimal. Moreover, in the setting of unsuspected malignancy, there is no evidence to prove that contained in-bag morcellation improves prognosis. Certain studies have proven that there can be spread of leiomyoma cells while dissecting out the myoma, even without morcellation. Also, studies have proven that a thorough irrigation of the peritoneal cavity can get rid of these tumour cells.

Conclusion

All existing tissue retrieval methods in laparoscopic surgery have pros and cons. The surgeon in consonance with the patient should find a balance between the two. It is difficult to single out one particular tissue extraction method is protective for all patients. Hence, at this point, all existing tissue retrieval methods should be available and further studies are needed for preoperative evaluation of uterine sarcomas and contained in-bag morcellation.

Suggested Readings

1. Muzii L et al. LAVH Vs minilaparotomy hysterectomy: a prospective randomized multicentre study. *J Minim Invasive Gynecol* 2007Sep-Oct;14(5):610-615.
2. Lawrence Lee, et al. Incidence of incisional hernia in the specimen extraction site for laparoscopic colorectal surgery: systematic review and meta-analysis; *Surg Endosc*: DOI 10.1007/s00464-017-5573-2(Apr 2017).
3. A Lambertz et al. Port-site incisional hernia - A case series of 54 patients; *Annals of Medicine and Surgery* 14(2017).
4. Kondo W. et al. Does prevention of intraperitoneal spillage when removing a dermoid cyst prevent granulomatous peritonitis? *BJOG* 2010;117:1027–1030.
5. Cristoforoni PM et al. Ovarian cystic teratoma: to scope or not scope? *J Gynecol Tech*. 1995;1:153–156.
6. Clemont D. et al Chemical peritonitis: a rare complication of an iatrogenic ovarian dermoid cyst rupture. *Surg Endosc*. 2003;17:658.
7. By Stefano Palomba. Et al. Port-site metastasis after laparoscopic surgical staging of endometrial cancer: a systematic review of the published and unpublished data; <http://www.AAGL.org/JMIG-19-04-12-00065>.
8. Kumar A. Minilaparotomy versus laparoscopy for gynaecologic conditions. *J Minim Invasive Gynecol* 2014 Jan-Feb;21(1):109-114.
9. Anici PB et al. Laparoscopy compared with laparoscopically guided minilaparotomy for large adnexal masses: a randomized controlled trial. *Obstet Gynecol* 2007;110:241–8.
10. Pillai R et al: Posterior colpotomy revisited: A forgotten route for retrieving larger benign ovarian lesions following laparoscopic excision. *Arch Gynecol Obstet* 2010; 281(4): 609-11.
11. Andreas S et al. Methods of specimen removal from the abdominal cavity after laparoscopic excision. *Obstet Gynaecol* 2013; 15:26-30.
12. Hodgson B, AAGL Practice report: Morcellation During Uterine Tissue Extraction, *The Journal of Minimally Invasive Gynecology*(2014). doi: 10.1016/j.jmig.2014.05.010.
13. Pelosi MA. The Proyer technique of uterine morcellation. *Int J Gynaecol Obstet* 1997 Sep;58(3):299-303.
14. Driessen SR et al. Electromechanical morcellators in minimally invasive gynecologic surgery: an update. *J Minim Invasive Gynecol*(2014) 21:377-83. doi:10.1016/j.jmig.2013.12.121
15. Brooks SE et al. Surveillance, epidemiology and end results analysis of 2677 cases of uterine sarcoma 1989-1999. *Gynecol Oncol* 2004 Apr;93(1):204-208.
16. Goto A, et al. Usefulness of Gd-DTPA contrast-enhanced dynamic MRI and serum determination of LDH and its isozymes in the differential diagnosis of leiomyosarcoma from degenerated leiomyoma of the uterus. *Int J Gynecol Cancer* 2002 JulAug;12(4):354-361.
17. Einarsson JJ, et al. In bag morcellation. *J Minim Invasive Gynecol*(2014) 21:951-3. doi:10.1016/j.jmig.2014.08.408.
18. Paul PG et al. Contained morcellation for laparoscopic myomectomy within a specially designed bag. *J Minim Invasive Gynecol*(2016) 23:257-60. doi:10.1016/j.jmig.2015.08.004.
19. Toubia T et al, Peritoneal Washings after Power Morcellation in Laparoscopic Myomectomy: A Pilot Study, *The Journal of Minimally Invasive Gynecology* (2016), doi: 10.1016/j.jmig.2016.02.001.
20. Steve P et al, Irrigation after Laparoscopic Power Morcellation and the Dispersal of Leiomyoma Cells: a Pilot Study, *The Journal of Minimally Invasive Gynecology* (2018), <https://doi.org/10.1016/j.jmig.2018.01.027>.

Minimally Invasive Surgeries in Gynaecological Oncology

Jayashree N¹, Neerja Bhatla²

¹Fellow, Gynaecologic Oncology, ²Professor, Dept of Obst & Gynae, AIIMS New Delhi

Introduction

Minimally invasive surgeries in gynaecological malignancies have been in practice for 40 years. The first use of laparoscopic methods in gynaecological oncology dates back to the 1970s. Diagnostic laparoscopy to assess the adnexal masses were performed initially^(1,2). The steps towards advanced surgeries progressed faster in 1980s with Professor Maurice Bruhat at Clermont-Ferrand developing techniques to include surgery on pelvic masses and tubal surgery. Reich described laparoscopic hysterectomy first time in 1989. In 1990 Dennis Querleu first reported on the use of laparoscopy in pelvic lymphadenectomy procedures in patients with cervical cancer⁽³⁾. Other reports soon followed, including a study on laparoscopy in paraaortic lymph node sampling, published by Herd and colleagues in 1992, and a publication in the same year by Nezhat et al, on laparoscopic radical hysterectomy to treat cervical carcinoma^(4,5). Since then, numerous laparoscopic gynaecologic oncology procedures have been carried out, and a number of studies have assessed the outcomes after minimally invasive surgical procedures. The improvement in designing of laparoscopic instruments especially power sources have made MIS, a comfortable and safe option for surgeons. The development of robotic technology was also a landmark improvement in minimal invasive approach. The dexterity of robotic arms and comfort of operating surgeon in robotics are encouraging additions for surgical gynaecological oncologists.

The advantages of laparoscopic surgeries including short hospital stay, early recovery, less blood loss, better cosmetic results were the need of the hour in gynaecological surgeries. These advantages of laparoscopy have to be weighed against the oncological principles, so that the choice of modality of surgery should not compromise the survival benefits. Various literature on cervical, endometrial and ovarian cancer management with laparoscopy has been published with the latest publication of LACC trial questioning the use of laparoscopy in cervical cancer. This article will review in detail the role of minimally invasive surgery in gynaecological oncology.

Role of Laparoscopy in Endometrial Cancer

Minimally invasive surgeries have been accepted as a standard modality of management of in patients with endometrial cancer. The better post-operative course with laparoscopy in endometrial cancer patients encourages surgeons to choose it as the modality of choice.

Large number of retrospective studies have validated the role of laparoscopic surgery in endometrial cancer. The GOG conducted a randomized control trial comparing laparoscopy and laparotomy for the comprehensive surgical staging of uterine cancer, the "LAP-2 trial" studied 2,616 patients who were randomly assigned to surgical staging of uterine cancer by either laparotomy (920 patients) or laparoscopy (1,696 patients). There was a 26% rate of conversion to laparotomy in the patients who were randomized to laparoscopy, primarily due to poor visibility. Patients in the laparoscopic arm did not have pelvic and aortic nodes removed in a higher percentage of patients when compared to the laparotomy group (8% vs. 4%, $P < 0.001$). There was no difference in the overall detection of advanced stage disease in the two groups. Despite having a longer operative time, the LAP-2 trial confirmed that hospital stay was shorter and there were fewer postoperative adverse events in the laparoscopic group. Laparoscopic surgery was also associated with an improved quality of life. In the follow-up study reporting on disease outcomes, the study was found to fall short of the protocol-specified definition of non-inferiority. The authors pointed out that the actual recurrence rates were substantially lower than anticipated; the 3-year recurrence rate was 11.4% with laparoscopy and 10.2% with laparotomy. The estimated 5-year overall survival rate was 89.8% in both arms, leading the authors to conclude that laparoscopy is a reasonable method to surgically treat patients with early stage uterine cancer⁽⁶⁾. Though time taken for surgery are more with laparoscopy, intraoperative complications are found similar in laparoscopy and laparotomy⁽⁷⁾.

Most of the endometrial cancer patients have obese body contour with multiple comorbidities. Kohler et al, showed the lymph node yield in these patients were

comparable to lymph node yield by laparotomy though the duration of surgery was more due to difficulty in exposing paraaortic region⁽⁸⁾. Study by Scribner et al, showed that in patients with age more than 65, laparoscopy was associated with decreased hospital stay, incidence of ileus, and infectious complications, with comparable blood loss and lymph node counts removed⁽⁹⁾.

Leitao et al. reported with a case series of 752 patients with newly diagnosed uterine cancer who underwent initial surgical management from 2007 to 2010. One hundred four (14%), 302 (40%), and 347 (46%) patients underwent planned laparotomy, laparoscopy, and robotic surgery, respectively. When comparing the preoperative characteristics of the laparoscopic and robotic cohorts, there was a high proportion of morbidly obese patients in the robotic group, 15% vs. 10%, $P=0.049$. The median total operating room time was higher for the robotic group versus the laparoscopic group (213 vs. 184 minutes, $P<0.001$). However, after accounting for a 40-case learning curve, these operating room times were similar. Median estimated blood loss was 50 mL for the robotic group compared to 100 mL for the laparoscopic ($P<0.001$). Median pelvic node counts were 13 (range, 3-34) and 15 (range, 3-48) for the robotic and laparoscopic groups respectively ($P=0.03$). Median postoperative stay was 1 day (range, 0-5 days) for the robotic group compared to 2 days (range, 1-15 days) for the laparoscopic group ($P<0.001$). Interestingly, the increased use of robotic surgery from 8% to 64% of the newly diagnosed uterine cancer population coincided with a decrease in the use of planned laparotomy from 24% to 9%. The reduction in conversion to laparotomy may convert in to cost saving⁽¹⁰⁾.

In a retrospective cohort of 1150 patients operated between 2009 and 2015, Chamber LM et al, showed that there was no difference in progression free survival or overall survival in women undergoing surgery for endometrial cancer via robotic-assisted laparoscopy, single port laparoscopy, multiport laparoscopy⁽¹¹⁾. In a prospective RCT by Lundin VS robotic hysterectomy in the setting of an enhanced recovery after surgery program led to faster recovery in health-related quality of life compared with abdominal hysterectomy⁽¹²⁾ 50 women with low-risk endometrial cancer scheduled for surgery between February 2012 and May 2016 were included in a randomized trial. Surgery was performed according to principles for minimal invasive surgery. Anesthesia and peri-operative care followed a standardized enhanced recovery after surgery program in both groups. The EuroQol Group form EQ-5D and the Short Form-36 were used to

evaluate patients' health-related quality of life. The Swedish Postoperative Symptoms Questionnaire assessed symptoms pre-operatively, daily for 7 days from the day of surgery, and then weekly until 6 weeks post-operatively. Data were analyzed by means of non-parametric tests and repeated measures ANOVA. To evaluate the time-dependent occurrence of complications, Kaplan-Meier survival and Cox proportional-hazard models were used. Results A total of 50 women were enrolled in the study (25 robotic and 25 abdominal hysterectomy).

Like any other medical treatment, Minimal invasive surgeries also have their own limitations. Anatomic barriers, such as large uteri that require morcellation, are contraindications to using laparoscopic surgery if endometrial cancer is present⁽¹³⁾.

Role of Laparoscopy in Cervical Cancer

Laparoscopic radical hysterectomy has been practised in many centres worldwide. Number of retrospective studies on laparoscopic and robotic surgery showed that minimal invasive surgery giving comparable results to open surgery⁽¹⁴⁻¹⁸⁾.

Fertility preserving Dargent's procedure which includes laparoscopic lymphadenectomy and vaginal radical trachelectomy showed comparable overall survival to radical hysterectomy. The laparoscopic or robotic abdominal trachelectomy with cervical encircage showed encouraging results in fertility outcomes⁽¹⁹⁾.

The latest evidences from two major studies and the retrospective analysis of multiple centres following that has brought a debate about the use of MIS in cervical cancer. The first evidence was from the MD Anderson Cancer Center and was an examination of the Surveillance, Epidemiology & End Result (SEER) database from the USA. In this retrospective study of 2221 women, the 4-year mortality risks were 5.8% for open surgery and 8.4% in the minimal invasive surgical arm, respectively. The hazard ratio (HR) was 1.48 (95% CI 1.10-1.98)⁽²⁰⁾. Following which the results of the prospective multicentre randomised control trial by Ramirez PT et al, rang the bells of warning against the minimally invasive surgery in cervical cancer⁽²¹⁾. In this study the early data from the Laparoscopic Approach to Carcinoma of the Cervix (LACC) study also showed improved survival with open radical hysterectomy for cervical cancer compared to a minimally invasive approach. The LACC study was a randomized controlled study powered to 90% to show non-inferiority for minimal

access radical hysterectomy at 4.5 years. The HR for disease-free survival was 3.74. The Data Safety Monitoring Committee stopped the trial prematurely after 85% recruitment considering the study results. Kim SI et al, in a retrospective data analysing 435 patients with stage IB1 cervical cancer, operated between 2000-2018, showed poor overall survival in MIS arm compared to open surgery arm. But MIS was not found to be a poor prognostic factor in patients with tumour <2cm.

With these study results, the societies and gynaecological oncology bodies including American Society of Gynaecological Endoscopy have given words of caution against the use of MIS in cervical cancer. The patients have to be adequately counselled about these study results showing poor outcome in overall survival with MIS in cervical cancer.

The 2018 FIGO staging has included lymph nodal disease in stage III⁽²²⁾. When patients have doubtful nodal involvement laparoscopy can be used to assess the nodal involvement. Nodal involvement has shown to reduce the survival. The assessment of nodal involvement by imaging may not be conclusive. Laparoscopic assessment of nodes may help to upstage the disease when involved hence in planning appropriate management. Uterus 11 study is a large prospective randomised study in which 255 women with advanced cervical cancer were included the feasibility and outcomes of surgical staging prior to radical chemoradiation among patients with locally advanced cervical cancer was studied. This study showed operative surgical staging upstaged 33% of women and it was safe without any delay in initiation of chemoradiation. The risk of port site metastasis in this method of laparoscopic staging may be the limiting factor⁽²³⁾.

Alfonso et al, 2019 in his nation-wide population-based study of 864 women (236 open and 628 robotic) from January 2011- December 2017 showed that the 5 years overall survival was 92% and 94% and DFS 84% and 88% for the women who underwent hysterectomy for Stage IA1-1b cervical cancer. Tumour size and grade were significant prognostic indicators in multivariate analysis⁽²⁴⁾.

With the evidences supporting and opposing minimally invasive surgery in cervical cancer it is essential counsel the patients adequately before proceeding with minimally invasive surgery.

Role of Laparoscopy in Ovarian Cancer

The role of minimally invasive surgery in ovarian cancer in various clinical scenarios in which patient

needs surgery differs. The risk of rupture of tumour upstaging the disease and port site metastasis limits the modality to limited situations. Surgery for ovarian cancer by minimally invasive approach may be contemplated in one of the following situations

- i) laparoscopic assessment of feasibility of upfront optimal surgical cytoreduction;
- ii) primary cytoreduction of early ovarian cancer;
- iii) primary cytoreduction of advanced ovarian cancer;
- iv) second look laparoscopy after primary treatment;
- v) assessment of extent of diseases and operability in recurrent disease.

In the evaluation of disease for feasibility of optimal cytoreduction diagnostic laparoscopy can help to assess disease extent and operability and provide tissue for definitive histopathological diagnosis. The risk of port-site metastasis was found to be high but this was not found to worsen the prognosis.⁽²⁵⁾

Melamed A et al studied 4798 patients from National Cancer Data Base with clinical stage I epithelial ovarian cancer diagnosed from 2010 through 2012 and underwent staging surgery, among them 1112 (23.2%) underwent procedures that were initiated laparoscopically, of which 190 (17%) were converted to laparotomy. time to death did not differ between patients undergoing planned laparoscopic vs open staging (hazard ratio, 0.77, 95% confidence interval, 0.54–1.09; $P = 0.13$). study confirmed that surgical staging via planned laparoscopy vs laparotomy was not associated with worse survival in women with apparent stage I epithelial ovarian cancer.⁽²⁶⁾ the practice remains controversial because of an absence of randomized trials and lack of high-quality observational studies demonstrating equivalent outcomes.

Objective

This study seeks to evaluate the association of laparoscopic staging with survival among women with clinical stage I epithelial ovarian cancer.

Study Design

We used the National Cancer Data Base to identify all women who underwent surgical staging for clinical stage I epithelial ovarian cancer diagnosed from 2010 through 2012. The exposure of interest was planned surgical approach (laparoscopy vs laparotomy)

Bogoni A et al conducted a systematic review and meta-analysis of studies on stage I ovarian cancer patients and concluded survival outcomes were not influenced by the route of surgery. Pooled data suggested that the minimally invasive surgical approach is equivalent to laparotomy for the treatment of eEOC and may be superior in terms of perioperative outcomes.⁽²⁷⁾

Falcetta FS et al in 2016 published the Cochrane review

on laparoscopy in early stage ovarian cancer. They did not find enough evidence to conclude since there were no randomised RCTs in this aspect.⁽²⁸⁾ Few case series on debulking surgeries in advanced ovarian cancer have been published. Laparoscopic approach was shown to have less blood loss, early bowel recovery and better post-operative course but the duration of surgery, conversion to laparotomy and the risk of port site metastasis are higher. Fanning et al reported successful cytoreduction in 23 patients (92%). Two procedures were converted to laparotomy because of extensive omental disease and bulky metastasis surrounding the rectosigmoid colon, respectively.⁽²⁹⁾ Davidson BA et al evaluated surgical complexity scores (SCS) and minimally invasive surgery (MIS) at interval debulking surgery (IDS) in advanced epithelial ovarian cancer (EOC) patients receiving neoadjuvant chemotherapy (NACT). Among 282 patients studied approximately 84% were optimally cytoreduced. Fifty-one patients underwent laparoscopic IDS. Twenty-four (47%) were converted to laparotomy to achieve optimal debulking in 21 patients (87.5%); while 25 had laparoscopic optimal cytoreduction (19/25 [76%]). Study concluded that in women with advanced EOC treated with NACT, older age, SCS ≥ 3 , and residual disease <1 cm at IDS were predictors of worse survival. MIS appears safe and feasible with acceptable optimal cytoreduction rates.⁽³⁰⁾

The second look laparoscopy after primary treatment of ovarian cancer was performed to confirm any residual disease. With the advent of advanced imaging second look laparotomies are not routinely practised now. Galetta et al published a retrospective cohort study on role of laparoscopy in recurrent setting. He studied 58 patients operated between October 2010 and October 2016. His study concluded that for selected patients, laparoscopy is a feasible and safe approach to optimal cytoreduction for patients with recurrent ovarian cancer.

Fagotti A et al, 2019 published the international Mission study: minimally invasive surgery in ovarian neoplasm after neoadjuvant chemotherapy, the aim of the study was to identify the feasibility, extent, and outcome of minimally invasive surgery at the time of interval debulking surgery, 127 women from five gynaecological centres participated in the study. All the patients who participated in the study had optimal cytoreduction. 122 (96.1%) had no residual tumour. Median operating time was 225 minutes (range 60-600) with median estimated blood loss of 100 ml (range 70-1320ml) with median time to discharge of 2 days (1-33 days), estimated median to start chemotherapy

was 20 days. (range 15-60). Six (4.7%) patients had intraoperative complications. Authors concluded that minimal invasive surgery can be considered in women with advanced ovarian cancer who undergo surgery after neoadjuvant chemotherapy. ESMO recommends minimal invasive surgery in restaging, whatever the approach used intact tumor must be removed without spill of cancer cells.

Conclusion

Minimally Invasive Surgery in Gynaecological Oncology has been an evolving subject with topics of arguments over decades. Optimal patient selection, adequate counselling, expertise and adhering to oncological principles will provide good outcome with minimal invasive surgeries. Use of minimally invasive approach in endometrial cancer is supported by adequate literature. Evidences for the role of minimally invasive approach in ovarian cancer is evolving. The randomised control trial on minimally invasive study in cervical cancer has shown low overall survival for minimally invasive surgery compared to open approach. Hence at present minimally invasive surgery in cervical cancer should be used only in research setting with adequate patient counselling. Multicenter studies in this subject are needed to strengthen the available evidence.

References

1. Spinelli P, Luini A, Pizzetti P. et al. Laparoscopy in staging and restaging of 95 patients with ovarian carcinoma. *Tumori*. 1976;62:493–501.
2. Rosenoff SH, Young RC, Anderson T. et al. Peritoneoscopy: a valuable staging tool in ovarian carcinoma. *Ann Intern Med*. 1975;83:37–41.
3. Querleu D, Leblanc E, Castelain B. Pelvic lymphadenectomy under celioscopic guidance. *J Gynecol Obstet Biol Reprod*. 1990;19:576–578.
4. Herd J, Fowler J M, Shenson D. et al. Laparoscopic para-aortic lymph node sampling: development of a technique. *Gynecol Oncol*. 1992;44:271–276.
5. Nezhat C R, Burrell M O, Nezhat F R. et al. Laparoscopic radical hysterectomy with paraaortic and pelvic node dissection. *Am J Obstet Gynecol*. 1992;166:864–865.
6. Walker JL, Piedmonte MR, Spirtos NM, et al. Recurrence and survival after random assignment to laparoscopy versus laparotomy for comprehensive surgical staging of uterine cancer: Gynecologic Oncology Group LAP2 Study. *J Clin Oncol*. 2012;30:695Y700.
7. Zullo F, Falbo A, Palomba S. Safety of laparoscopy vs laparotomy in the surgical staging of endometrial cancer: a systematic review and metaanalysis of randomized controlled trials. *Am J Obstet Gynecol*. 2012;207:94Y100.
8. Kohler C, Tozzi R, Klemm P, Schneider A. Laparoscopic

- paraortic left-sided transperitoneal infrarenal lymphadenectomy in patients with gynaecological malignancies: techniques and results. *Gynecol Oncol.* 2003; 91:139-148.
9. Scribner DR, Walker JL, Johnson GA, McMeekin SD, Gold MA, Mannel RS et al. Laparoscopic pelvic and paraortic lymphnode dissection: analysis of first 100 cases. *Gynecol Oncol.* 2001;82(3):498-503.
 10. Leitaó MM, Briscoe G, Santos K, Lewell EI, Hoskins WJ, Chi DS, et al. Introduction of a computer-based surgical platform in the surgical care of patients with newly diagnosed uterine cancer: Outcome and impact on approach. *Gynecol Oncol.* 2012;125(2):394-399.
 11. Chambers LM, Carr C, Freeman L, Jernigan AM, Michener CM. Does surgical platform impact recurrence and survival? A study of utilization of multiport, single-port, and robotic-assisted laparoscopy in endometrial cancer surgery. *Am J Obs & Gynecol.* 2019; (221(3): 243.e1–243.e11.
 12. Lundin ES, Wodlin NB, Nilsson L, Kjölhede P. A prospective randomized assessment of quality of life between open and robotic hysterectomy in early endometrial cancer. *Int J Gynecol Cancer.* 2019. pii: ijgc-2019-000285.
 13. Rossi EC, Kowalski LD, Scalici J, Cantrell L, Schuler K, Hanna RK, et al. A comparison of sentinel lymph node biopsy to lymphadenectomy for endometrial cancer staging (FIRES trial): a multicentre, prospective, cohort study. *Lancet Oncol.* 2017;18(3):384–92.
 14. Wang YZ, Deng L, Xu HC, Zhang Y, Liang ZQ. Laparoscopy versus laparotomy for the management of early stage cervical cancer. *BMJ Cancer.* 2015;15:928.
 15. Zanagnolo V, Minig L, Rollo D, Tomaselli T, Aletti G, Bocciolone L, et al. Clinical and oncologic outcomes of robotic versus abdominal radical hysterectomy for women with cervical cancer: experience at a referral cancer center. *Int J Gynecol Cancer.* 2016;26:568-74.
 16. Wallin E, Flöter Rådestad A, Falconer H. Introduction of robot-assisted radical hysterectomy for early stage cervical cancer: impact on complications, costs and oncologic outcome. *Acta Obstet Gynecol Scand.* 2017;96:536-42.
 17. Shah CA, Beck T, Liao JB, Giannakopoulos NV, Veljovich D, Paley P. Surgical and oncologic outcomes after robotic radical hysterectomy as compared to open radical hysterectomy in the treatment of early cervical cancer. *J Gynecol Oncol.* 2017;28:e82.
 18. Gortchev GT, Tomov S, Tantchev L, Velkova A, Radionova Z. Robot-assisted radical hysterectomy— perioperative and survival outcomes in patients with cervical cancer compared to laparoscopic and open radical surgery. *Gynecol Surg.* 2012;9:81-8.
 19. Bentivegna E, Maulard A, Pautier P, Chargari C, Gouy S, Morice P. Fertility results and pregnancy outcomes after conservative treatment of cervical cancer: a systematic review of the literature. *Fertil Steril.* 2016;106(5):1195-1211.
 20. Rauh-Hain JA. Comparative effectiveness of minimally invasive staging surgery in women with early stage cervical cancer. *Proceedings of the Society of Gynecologic Oncologists*, Mar 2018.
 21. Ramirez PT, Frumovitz M, Pareja R, Lopez A, Vieira M, Ribeiro R, et al. Minimally Invasive versus Abdominal Radical Hysterectomy for Cervical Cancer. *NEJM.* 2018 Nov 15;379(20):1895–904.
 22. Bhatla N, Berek JS, Fredes MC, Denny LA, Grenmann S, Karunaratne K, et al. Revised FIGO staging for carcinoma of the cervix uteri. *Int J Gynecol Obstet.* 2019;145(1):129-135.
 23. Marnitz S, Martus S, Kohler C, Stromberger C, Asse E, Mallmann P et al. Role of surgery versus clinical staging in chemoradiation in chemoradiated FIGO stage IIB-IVA cervical cancer patients, acute toxicity and treatment quality of the Uterus-11 multicenter phase III intergroup trial of the German Radiation Oncology Group and the Gynaecological cancer Group. *Int J radiation Oncol Bio Phys.* 2016;94(2):243-53.
 24. Alfonso A, Wallin E, Ekdahl L, Staf C, Radeshed AF, Reynisson P et al. No survival difference between robotic and open radical hysterectomy for women with early stage cervical cancer: results from a nation wide population based cohort study. 2019;116;169-177.
 25. Vergote I, Marquette S, Amant F, et al. Port-site metastases after open laparoscopy: a study in 173 patients with advanced ovarian carcinoma. *Int J Gynecol Cancer.* 2005;15:776–9.
 26. Melamed A, Keating NL, Clemmer JT, Bregar AJ, Wright JD, Boruta DM, et al. Laparoscopic staging for apparent stage I epithelial ovarian cancer. *American Journal of Obstetrics and Gynecology.* 2017;216(1):50.e1-50.e12.
 27. Nezhat FR, DeNoble SM, Liu CS, et al. The safety and efficacy of laparoscopic surgical staging and debulking of apparent advanced stage ovarian, fallopian tube, and primary peritoneal cancers. *JSLS.* 2010; 14:155–168.
 28. Laparoscopy versus laparotomy for FIGO stage I ovarian cancer - Falcetta, FS - 2016 | Cochrane Library. Available from: <https://www.cochranelibrary.com/cdsr/doi/10.1002/14651858.CD005344.pub4/abstract>. [Accessed on 20 Sep 2019].
 29. Fanning J, Yacoub E, Hojat R. Laparoscopic-assisted cytoreduction for primary ovarian cancer: success, morbidity and survival. *Gynecol Oncol.* 2011;123:47–49.
 30. Davidson BA, Broadwater G, Crim A, Boccacio R, Bixel K, Backes F, et al. Surgical complexity score and role of laparoscopy in women with advanced ovarian cancer treated with neoadjuvant chemotherapy. *Gynecologic Oncology.* 2019 Mar 1;152(3):554–9.

Introduction to Robotics

Vinod Nair¹, Kallol Kumar Roy², Anamika Das³

¹Fellow MIGS, ²Professor and Head of MIGS Unit, ³Senior Resident, Dept of Obst & Gynae, AIIMS New Delhi

Introduction

Robotic surgery is the latest addition to the armamentarium of Minimally Invasive Gynaecological Surgery. Robotics was introduced to surgical field with a vision of preserving the benefit to the patient of endoscopic surgery while giving back to the surgeon the benefit of dexterity of open surgery. There have been speculations regarding advantages and disadvantages of robotic surgery vis a vis conventional laparoscopy. A three dimensional, magnified and stable camera vision along with superior instrumentation achieved by EndoWrist technology makes robotic surgery one step ahead. Moreover, from ergonomics point of view, a seated surgical environment causes less fatigue through prolonged surgeries. However, along with so many other factors, the cost effectiveness takes paramount importance while considering robotics to replace otherwise laparoscopically feasible gynaecological surgeries.

The Da Vinci Robotic System

The 'da Vinci surgical system' is a sophisticated robotic platform introduced in 1999. It was approved by US-FDA in 2005 for use in minimally invasive surgery. The system evolved into 'da Vinci S' in 2006 with 3D HD vision. The 'da Vinci Si' system with dual console option was introduced in 2009. The latest platform is 'da Vinci Xi' (Fig-1) introduced in 2014 with multi-quadrant access, 'chip-on-tip' 3D HD vision and integrated energy. The system has three main components; the surgeon console, the patient cart and the vision cart.

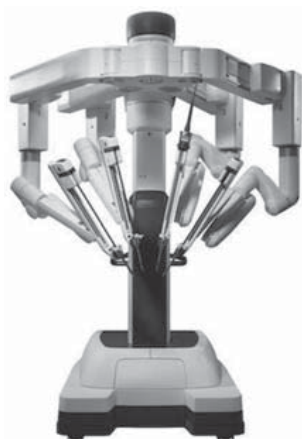

Fig-1 : da Vinci Xi Surgical system

The Surgeon Console

The surgeon console has three components; a pair of master controllers, the footswitch panel and the stereoviewer. The surgeon sits at the console away from the patient's cart and operates using hands and feet with the help of two master controllers and foot pedals. The console is designed in such a way as to mimic the hand-eye coordination of open surgery. Optimum hand-eye coordination is achieved by the perception of alignment of the tips of robotic instruments with a virtual extension of the master controllers. The surgeon operates the master controllers with the help of ipsilateral index finger and thumb. All the movements of master controllers are replicated real time at the surgical field through the robotic instruments.



Fig-2: Surgeon's console

The stereoviewer has a pair of oculars through which the surgeon gets a clear, high definition, magnified and three dimensional view of the surgical field. The right and left visual inputs from the dual-channel robotic endoscope are integrated to provide the surgeon an adequate depth perception extending his vision into the surgical field. Furthermore, the stereoviewer provides ergonomic support to the surgeon's head and also displays messages concerning functional status of the system and instruments.

The footswitch panel has two groups of pedals on each side. The right group, operated by the surgeon's right foot, has two pairs of lower blue and upper yellow pedals for controlling the energy activation and deactivation of instruments. The yellow and blue pair of pedals on the left controls the energy activation

and mode (cutting or coagulation) of the instruments controlled through the left master controller and vice versa.

The left group of foot switch pedals, operated by the surgeon's left foot, has three black pedals for controlling the system functions such as camera control, arm swap and master clutch. Repositioning of the robotic endoscope and zooming of the camera are done by camera control panel. When the camera control panel is pressed, the master controller is disengaged from the instrument control mode and changes to camera control mode. During camera control mode, simultaneous parallel movements of the master controllers result in movements of the endoscope. Zoom is achieved when the controllers are simultaneously pulled towards the surgeon's eyes. The master clutch pedal, located above the camera control pedal, is used to disengage all the instruments from the master controller so as to allow the surgeon to reposition the master controllers for better ergonomic comfort and spatial orientation. The arm swap pedal when tapped, the control between two instrument arms associated with the same master controller is swapped.

In addition to these, a touch pad is located in the middle of the console's armrest to provide the surgeon means to make system adjustments such as brightness, digital zoom and movement scaling. This touch pad can also perform functions such as camera set-up, manual configuration of instrument assignment to controllers etc. There are switches towards the left side of the armrest which can perform ergonomic controls such as height adjustment of stereo viewer, armrest and depth adjustment of foot-switch panel.

The Patient Cart

The operational component of the da Vinci surgical system is the patient cart. It has three instrument arms marked as 1, 2 & 3 and one camera arm. Each robotic arm has two main components; the set-up joint and the instrument arm. The set-up joint connects the instrument arm to the patient cart centre column. The instrument arm has a wide range of movements.

The Vision Cart

The da Vinci 3D HD vision system has three components; the da Vinci stereo dual channel endoscope, the HD stereo camera head with two optic channels and the vision cart illuminator. The video images of da Vinci HD vision system are high definition, three dimensional and 6-10 times magnified. The camera head is connected to the vision

cart via a bifurcated fibreoptic cable. The digital input is integrated at the surgeon console to provide a three dimensional view. There are two options for robotic endoscope; a 387mm long 8.5mm diameter one and a 454mm long 12mm diameter one. Both are available in 0° and 30° configuration.

Robotic Instruments

The da Vinci robotic instruments work with the principle of EndoWrist technology which can mimic human hand and wrist movements. This technology allows 180° of articulation, 7 degrees of freedom and 540° rotation. Endowrist instruments have four parts; the housing, the shaft, the wrist and the tip. The housing of the instrument, blue in colour, has attached release levers. The endowrist instruments are available in 5mm or 8mm shaft diameter and approximately measure 550-570mm length. The 8mm instruments have an 'angled joint' at the wrist whereas 5mm instruments have a 'snake joint'. These instruments include monopolar cautery, bipolar cautery, scissors, scalpel, graspers, needle drivers, clip applicator, suction-irrigator, stapler and some specialty instruments. All these instruments have predetermined number of uses, typically 1-10.

Similar to EndoWrist instruments, there are some Single-Site instruments specifically designed for da Vinci surgical system. These instruments have 5mm diameter semirigid shafts. The instrument tips of Single-Site instruments can rotate 360° by means of master controllers. The Single-Site instruments does not work with Endo-Wrist technology, the 'wristed' mode of the master controller is automatically deactivated with Single-Site instruments. Single-Site instruments which work in 'wristed' mode are currently not manufactured. The 'wristed' mode is not possible because of the flexible nature of these instruments. Presently available Single-Site instruments include bipolar cautery, monopolar cautery, scissors, graspers, dissectors, needle drivers, suction-irrigator and clip applicator.

In addition to these, there are certain accessory instruments required in both single port and multi port robotic surgeries. The cannulae used in robotic surgery are stainless steel reusable hollow devices with a straight or curved shaft. The cannulae with straight shaft are meant for EndoWrist instruments. These are available in 5mm and 8mm sizes for instruments of their corresponding sizes. In addition, there are 8.5mm and 12mm cannulae for robotic endoscopes and 13mm for stapler. The curved cannulae are meant for Single-Site surgery and are 5mm in diameter. Single-Site

port is another accessory instrument used in Single-Site surgery which is made of pliable material and can be inserted through a 2.5cm umbilical incision. This port has four lumina for cannulae insertion and a fifth lumen for robotic endoscope cannula.

Draping and Docking

The instrument arms and camera arm should be draped before the patient cart is moved to the operating table. For draping purpose, three instrument arm drapes and one camera drape are required. The instrument drapes are opened and lowered over the instrument arm insertion axis while maintaining sterility. There is a sterile adaptor on all these instrument arm drapes. The base of the adaptor is aligned and clicked with the black moulded portion of the instrument arm. Correct fitting of the adaptor can be recognised by automatic spinning of four wheels on the adaptor and three beeps by the system. Now, the whole length of the instrument arm is covered by unfolding the drape over it. In a similar fashion, camera arm also is draped. For draping the camera head, mutual assistance of a sterile and a non-sterile person is required. The camera head drape is sterile and has an adaptor attached with it. The sterile person inserts his hand into the drape and holds one end of the adaptor while the non-sterile person aligns and locks the camera head with the adaptor. The entire drape is then inverted over the camera head and pulled along to cover the cables.

Patient positioning is of utmost importance in robotic surgery, as it would not be possible to change the patient's position once the docking has been done. Moreover, in robotic surgery, the patient is at risk of inadvertent mechanical injury to face and extremities. This is more so when the surgeon sitting at the console is unaware of the surgical environment. Hence, it is crucial for the surgeon and his team to be able to keep the patient trolley in completely visible location and maintain constant awareness of robotic arm movements. Usually, a low dorsal lithotomy position with both arms tucked by the sides is employed in gynaecological surgeries. Routinely, steep Trendelenburg positioning is employed for adequate visualisation of pelvic structures.

Docking is a maneuver in which the patient's cart is moved upto the operating table and robotic camera and other robotic instrument arms are attached to the corresponding cannulae. Docking is the most important step in robotic surgery as optimal docking is essential for maximum range of movements of robotic instruments as well as for avoiding collision

between instruments. There are mainly two methods of docking; center docking and side docking. Center docking is done by moving the patient cart between the legs of the patient. Once the camera cannula mount of the camera arm reaches above the camera cannula, the patient cart is at an appropriate distance from the patient. There are latches on the camera mount of the camera arm in which the camera cannula fits in. The surgeon can assist in the mounting process by pressing the camera clutch pedal at the console in order to achieve proper alignment of the camera arm with the camera cannula. Care should be taken to keep the tower of the patient cart aligned with the camera cannula and the target anatomy in straight line. Also, it is important to keep a sufficient distance between camera arm remote center and the patient cart tower. Otherwise, optimal range of motion will be impaired. This process is called setting up the 'sweet spot' which is indicated by a blue line and a corresponding arrow at the center of the camera arm set up joint. The position of camera arm is adjusted in such a way that the arrow comes within the boundaries of the blue line. The next step is to connect the instrument arms. Instruments arms are positioned with number markings and adaptor facing forward. The instrument arms can be connected all at once or one by one in any order. It is advisable to connect the number 3 instrument arm lastly to avoid spatial crowding. Again, the surgeon at the console can assist by pressing the instrument arm clutch pedal while aligning the cannula mount on the instrument arm with the cannula. There are latches on the cannula mount where cannula fits in. In order to minimise collision, maximum distance between the set up joints of the arms should be ensured. After proper docking, all numbers of the instrument arms should be facing forward and the second set up joint should make 90° angle.




Fig-3: Port placement and docking

Eventhough a simple procedure, center-docking prevents vaginal access which is quite important in gynaecological surgeries. Side docking is a suitable alternative for gynaecological surgeries where vaginal

access is required. In this technique, the patient cart is docked at 45° angle to the patient's torso. Docking can be done on either side of the patient depending on the surgeon's preference and the procedure to be performed. The rest of the docking procedure is same as center docking. On completion, the number markings should be facing sideways and the second set up joint should be completely extended.

Single-Site docking, as the name suggests, employed in Single-Site surgery, is different from centre docking and side docking. Here, cannula insertion and docking take place concurrently and in specific order and also curved cannulae are inserted under endoscopic vision. Another unique feature is the presence of 'orientation tab' at the base of the curved cannula to guide the mounting process. The curved cannulae and the camera cannula cross over at a specific point known as 'remote center'.

Conclusion

Since robotic surgery is a recent surgical technique in the field of minimally invasive surgery, it is prudent to have an in-depth knowledge of the robotic instrumentation and surgical techniques involved in it.

It will be too early to give a verdict that robotic surgery is going to replace laparoscopy. The author has a view that any gynaecological procedure which is technically feasible with laparoscopic technique, should be done by laparoscopy only and not by robotics. There are certain areas where robotic surgery has advantages over laparoscopy and there should be no restriction to the use of robotics in those cases. Needless to say, availability, cost factor and lack of expertise adversely affect the popularity of robotic surgery in developing nations.

Suggested Readings

1. Higuchi TT, Gettman MT. Robotic instrumentation, personnel and operating room setup. In: Li-Ming Su (ed), Atlas of robotic urologic surgery.
2. Strother E, Najam F, Gharagozloo F et al. Operating room setup and robot preparation. In: Gharagozloo F, Najam F (eds). Robotic Surgery. New York: The McGraw-Hill Companies, 2009; 14-30.
3. Einarsson et al. Side docking; an alternative docking method for gynaecological robotic surgery. Rev Obstet Gynecol 2011; 4(3-4):123-125.
4. da Vinci surgical system user manual by Intuitive Surgical Inc.

Scar Ectopic Pregnancy

Dinesh Kansal¹, Pooja Gupta²

¹Head of the Dept, Dept of Obst & Gynae, ²Associate Consultant, BLK Hospital, New Delhi

Introduction

Caesarean scar pregnancy (CSP) is a rarest form of ectopic pregnancy, with incidence ranging from 1/1800 to 1/2500 of all the pregnancies^{1,2}, 0.15% in women with previous pregnancy and 6.1% of all ectopic pregnancy. In this the gestational sac is fully or partially implanted within the scar caused by a previous caesarean section (CS). Larsen Jv first reported a case of CSP in 1978 in a patient with post abortal haemorrhage³. The cases of CSP have been increasing over a period of time, this has been ascribed with increased elective caesarean section and also due to increased awareness and improved detection with transvaginal ultrasound^{4,5}. The reason for its occurrence is still not known exactly but poor healing of scar is considered a major cause for this. It was found by Shen et al in 2012 in a case series of 45n that multiple caesarean surgery didn't increase the incidence of CSP, and a systemic review by Rotas et al conferred that the incidence after 1st Caesarean was 52 % of cases, 36 % in prior two caesarean section and 12 % after three or more prior caesarean section. Recurrence of CSP has been reported as 3.2–5.0% in women with one previous CSP treated by dilatation and curettage with or without uterine artery embolisation.^{6,7} Until recently CSP and placenta percreta were known as two different entities, but the latest data suggest them to be a consequence of single abnormality. If an expectant attitude is assumed for CSP than it will probably lead to pregnancy with placenta percreta in the scar and in the lower segment.

Etiopathogenesis

The exact cause & mechanism is still unknown, but literature supports the theory of scar pregnancy occurring due to formation of microtubular tract due to poor healing after surgical intervention. It is not only limited to caesarean section but can occur even after dilatation & curettage, hysterotomy, myomectomy, abnormal placentation & manual removal of placenta⁸. Women who elect to have a CS because of breech presentation in a previous pregnancy appear to be most frequently at risk of future CSP⁵. This may be related to the need for a higher uterine incision because of a poorly formed lower segment⁵.

Clinical Presentation & Diagnosis

Vaginal bleeding & abdominal pain are the most

common presenting features, although 40% patient remains asymptomatic prior to detection. Diagnosis is based on symptoms, clinical manifestation, history of previous scar, Serum β HCG level & Ultrasound imaging (combined transabdominal & transvaginal scan). Accuracy of Ultrasonography is 84.6% in detection of early CSP⁵. Timor et al described an ultrasound criteria for diagnosing CSP, listed in table 1⁹.

Table 1

Ultrasound criteria for diagnosis of caesarean scar pregnancy (CSP)
– Empty uterine cavity and closed and empty cervical canal
– Placenta and/or a gestational sac embedded in the scar of a previous caesarean section
– A triangular/round or oval-shaped gestational sac that fills the niche of the scar
– A thin or absent myometrial layer between the gestational sac and the bladder
– Yolk sac, embryo and cardiac activity may or may not be present
– Evidence of functional trophoblastic/placental circulation on colour flow Doppler examination, characterised by high velocity and low impedance blood flow

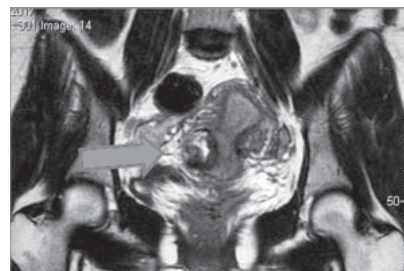


Image 1. MRI showing Rt. Lateral Ectopic Pregnancy

Magnetic resonance imaging (MRI) (image1) is also a useful adjunct for the diagnosis of CSP. MRI provides crucial information in cases where accurate diagnoses by ultrasound scan are difficult, such as in women with large fibroids or at a later stage of gestation¹⁰⁻¹²

Classification

CSP can be classified into two types based on imaging findings and pregnancy progression^{10,13}. Type 1, or endogenic, CSP is where implantation occurs on the scar and the gestational sac grows towards the cervico-isthmus or uterine cavity. Type 2, or exogenic CSP occurs when the gestational sac is deeply embedded in the scar and the surrounding myometrium and grows towards the bladder. In exogenic types, a layer

of myometrium may be seen between the gestational sac and the bladder at an earlier stage; this becomes thin and eventually disappears, with bulging of the gestational sac through the gap as the pregnancy progresses, thus carrying a greater risk of earlier rupture. In two-thirds of cases the thickness of the scar may be less than 5 mm¹⁴.

Differential Diagnosis

Cervical ectopic & inevitable miscarriages with low lying sac should be kept in differentials whenever in doubt of CSP. The early phase of a miscarriage can mimic CSP, but will have absent or minimal colour Doppler flows along with presence of “sliding sign” wherein gentle pressure at the level of internal os may displace the gestational sac but not the CSP or cervical ectopic¹⁵. A cervical ectopic pregnancy is present in or close to the cervical canal, with ballooning of the cervix with good Doppler flow and negative sliding sign may be seen.

Management

Treatment of CSP can be both medical & surgical depending on various factors like gestational age & size, severity of implantation anomaly, patient's physiological status, and patient's desire for pregnancy in future.

Medical Management

Conservative treatment should be offered in hemodynamically stable patients without pain, with a gestation age <8 weeks, myometrium thickness less than 2 mm between the pregnancy and the bladder, serum hCG <5,000 IU/L, GS%2.5 cm, and/or a fetus without heart action^(16,17).

Systemic methotrexate (MTX) for CSP
methotrexate: Dosage & Schedule of MTX is same as for tubal ectopic pregnancy with constant follow up of Beta HCG. Following the initial dose of methotrexate, hCG levels may go up and the size of the mass may increase due to trophoblastic necrosis and haemorrhage around the sac^{18,19}.

Systemic and local MTX. Local injection of MTX, can be used transabdominally or transvaginally²⁰. A 20–22-G needle is used; both procedures are performed under local analgesia. Local injection of MTX results in a higher MTX concentration at the CSP and a more rapid termination of the pregnancy²¹.

Treatment by needle aspiration and MTX. Potassium chloride, etoposide and hyperosmolar

glucose local administration. The gestational sac is aspirated transvaginally by ultrasound guidance²².

Uterine artery embolization: Uterine artery embolization can be done along with the local or systemic methotrexate or during or after surgical removal of CSP to prevent haemorrhage. Both uterine arteries can be embolized with gelatin sponge particles. Shen et al reported 45 cases with good success rate; only one woman required hysterectomy for bleeding²³.

High-intensity focused ultrasound. The procedure can be performed with ablation alone or in combination with hysteroscopic D&C^{24,25}. The initial procedure is performed under conscious sedation. A transducer produces the therapeutic energy required. Real-time ultrasound is used to target the area of the GS and monitor the response. Additional D&C is performed in general anesthesia.

Surgical Management

Surgical Evacuation: Surgical evacuation is suitable for endogenous CSP with myometrial thickness of more than 2 mm. It should be done under ultrasound guidance to aid complete tissue removal. Various techniques like UAE with methotrexate, intrauterine Foley's catheter and Shirodkar's sutures can be done at the time of evacuation to reduce bleeding²⁶.

Resection of CSP through a transvaginal approach: The bladder is dissected away through an incision in the anterior cervico-vaginal junction, and the CSP is identified in the anterior part of the lower uterine segment. The ectopic pregnancy tissue is removed through a transverse incision, and suction curettage through the incision on the uterus can be performed. Finally, the myometrial and vaginal defects are repaired²⁷.

Hysteroscopic management: It can be done as primary treatment to remove CSP mass or sequential treatment following an interval after methotrexate or UAE²⁸. UAE or laparoscopic uterine artery ligation could be performed immediately prior to hysteroscopic resection to reduce blood loss. Hysteroscopic resection can be combined with laparoscopic excision for complete removal of the mass, particularly in exogenous CSP^{29,30}.

Laparoscopy: Laparoscopic procedure is the mainstay in management of Scar Ectopic (Image 2). It is performed under general anesthesia and has been used in exogenous CSP with progression toward the bladder. It has a specific advantage with respect to the removal of the products of conception and the possibility of

repairing the myometrial defect at the same time. Excision and repair of old scar result in removal of microtubular tract and thus reduce the risk of recurrence. To avoid heavy perioperative bleeding, bilateral ligation of the uterine arteries may also be performed²⁹ (Image 3). Following surgical excision, b-hCG levels quickly return to normal and early discharge from follow up is possible. Since this approach is minimally invasive so the recovery is faster but requires expertise in advanced laparoscopic surgery³¹.




Image 2: Laparoscopic picture showing Rt Lateral Scar Ectopic



Image 3: Laparoscopic Uterine artery clipping at its origin

Followup

The patient should be followed up till normalisation of Beta HCG and resolution of CSP mass. Follow up may vary according to the treatment given. Normalisation of Beta HCG may take 6 weeks in conservative treatment but normalises faster in surgical excision of mass.

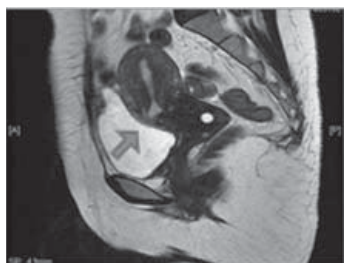

Image 4: MRI picture showing Isthmoele

Caesarean scar defect (isthmoele) (Image 4) is a fluid filled, pouch like abnormality at anterior abdominal wall at prior caesarean section scar. It can be diagnosed by TVS or MRI. This can be repaired at the time of laparoscopic removal of CSP. In others, prior to any future pregnancy, excision of scar tissue followed by interval resuturing of the defect should be done.

Conclusion

CSP is a rare condition but is increasing day by day due to increase in caesarean section rate. It represents a diagnostic and therapeutic challenge. Accurate early diagnosis and effective management are important to reduce maternal morbidity and mortality. Effective treatment of CSP should be carried out in first trimester to achieve the optimal treatment objectives including proper suturing of scar defect and prevent recurrence.

References

1. Seow KM, Huang LW, Lin YH, Lin MY, Tsai YL, Hwang JL. Caesarean scar pregnancy: issues in management. *Ultrasound ObstetGynecol*2004;23:247–53.
2. Jurkovic D, Hillaby K, Woelfer B, Lawrence A, Salim R, Elson CJ. First trimester diagnosis and management of pregnancies implanted into the lower uterine segment Caesarean section scar. *Ultrasound Obstet Gynecol*2003; 21:220–7.
3. Larsen JV, Solomon MH. Pregnancy in a uterine scar sacculus—an unusual cause of postabortal haemorrhage. *S Afr Med J* 1978;53:142–3.
4. Ash A, Smith A, Maxwell D. Caesarean scar pregnancy. *BJOG*. 2007 Mar;114(3):253-263.
5. Rotas MA, Haberman S, Levгур M. Cesarean scar ectopic pregnancies: etiology, diagnosis, and management. *Obstet Gynecol*. 2006 Jun;107(6):1373- 1381.
6. Qian ZD, Guo QY, Huang LL. Identifying risk factors for recurrent caesarean scar pregnancy: a case-control study. *FertilSteril* 2014;102: 129–134.e1
7. Ben Nagi J, Helmy S, Ofili-Yebovi D, Yazbek J, Sawyer E, Jurkovic D. Reproductive outcomes of women with a previous history of Caesarean scar ectopic pregnancies. *Hum Reprod*2007;22:2012–5.
8. Rosen T. Placenta accreta and cesarean scar pregnancy: overlooked costs of the rising cesarean section rate. *ClinPerinatol*. 2008; 35(3): 519–29.
9. Timor-Tritsch IE, Monteagudo A, Santos R, Tsymbal T, Pineda G, Arslan AA. The diagnosis, treatment, and follow-up of caesarean scar pregnancy. *Am J ObstetGynecol*2012; 207:44.e1–13.
10. Peng KW, Lei Z, Xiao TH, Jia FG, Zhong WX, Gao Y, et al. First trimester caesarean scar ectopic pregnancy evaluation using MRI. *ClinRadiol*2014;69:123–9.
11. Valley MT, Pierce JG, Daniel TB, Kaunitz AM. Caesarean scar pregnancy: imaging and treatment with conservative surgery. *ObstetGynecol*1998;91:838–40.
12. Uysal F, Uysal A, Adam G. Caesarean scar pregnancy: diagnosis, management, and follow-up. *J Ultrasound Med* 2013;32:1295–300.
13. Vial Y, Petignat P, Hohlfeld P. Pregnancy in a caesarean scar. *Ultrasound ObstetGynecol*2000;16:592–3.
14. Weimin W, Wenqing L. Effect of early pregnancy on a previous lower segment caesarean section scar. *Int J Gynecol Obstet* 2002;77:201–7.

15. Maymon R, Halperin R, Mendlovic S, Schneider D, Herman A. Ectopic pregnancies in a caesarean scar: review of the medical approach to aniatrogenic complication. *Hum Reprod Update* 2004;10:515–23.
16. Peng P, Gui T, Liu X, Chen W, Liu Z. Comparative efficacy and safety of local and systemic methotrexate injection in cesarean scar pregnancy. *Ther Clin Risk Manag* 2015;11: 137–42.
17. Gao L, Huang Z, Gao J, Mai H, Zhang Y, Wang X. Uterine artery embolization followed by dilation and curettage within 24 hours compared with systemic methotrexate for cesarean scar pregnancy. *Int J Gynaecol Obstet* 2014;127: 147–51
18. Timor-Tritsch IE, Monteagudo A. Unforeseen consequences of the increasing rate of caesarean deliveries: early placenta accreta and caesarean scar pregnancy: a review. *Am J Obstet Gynecol* 2012;207:14–29
19. Deb S, Clewes J, Hewer C, Raine-Fenning N. The management of caesarean scar ectopic pregnancy following treatment with methotrexate – a clinical challenge. *Ultrasound Obstet Gynecol* 2007;30:889–92.
20. Li N, Zhu F, Fu S, Shi X. Transvaginal ultrasound-guided embryo aspiration plus local administration of low-dose methotrexate for caesarean scar pregnancy. *Ultrasound Med Biol* 2012;38:209–13.
21. Timor-Tritsch IE, Khatib N, Monteagudo A, Ramos J, Berg R, Kovacs S. Cesarean scar pregnancies: experience of 60 cases. *J Ultrasound Med* 2015;34: 601–10.
22. Wang JH, Xu KH, Lin J, Xu JY, Wu RJ. Methotrexate therapy for cesarean section scar pregnancy with and without suction curettage. *Fertil Steril* 2009; 92:1208–13.
23. Shen L, Tan A, Zhu H, Guo C, Liu D, Huang W. Bilateral uterine artery chemoembolization with methotrexate for caesarean scar pregnancy. *Am J Obstet Gynecol* 2012;207: 386.e1–6.
24. Zhu X, Deng X, Wan Y, Xiao S, Huang J, Zhang L, et al. High-intensity focused ultrasound combined with suction curettage for the treatment of cesarean scar pregnancy. *Medicine (Baltimore)* 2015;94:e854.
25. Xiao J, Zhang S, Wang F, Wang Y, Shi Z, Zhou X, et al. Cesarean scar pregnancy: noninvasive and effective treatment with high-intensity focused ultrasound. *Am J Obstet Gynecol* 2014;211:356.e1–7.
26. Jurkovic D, Ben-Nagi J, Ofilli-Yebovi D, Sawyer E, Helmy S, Yazbek J. Efficacy of Shirodkar cervical suture in securing haemostasis following surgical evacuation of Caesarean scar ectopic pregnancy. *Ultrasound Obstet Gynecol* 2007;30:95–100.
27. Huanxiao Z, Shuqin C, Hongye J, Hongzhe X, Gang N, Chengkang X, et al. Transvaginal hysterotomy for cesarean scar pregnancy in 40 consecutive cases. *Gynecol Surg* 2015;12:45–51.
28. Chen ZY, Zhang XM, Xu H, Zhang J, Huang XF. Management of caesarean scar pregnancy by hysteroscopy combined with uterine artery embolism. *Chin J Obstet Gynecol* 2011;46:591–4.
29. Wang HY, Zhang J, Li YN, Wei W, Zhang DW, Lu YQ, Zhang HF et al. Laparoscopic management or laparoscopy combined with transvaginal management of type II caesarean scar pregnancy. *JSLs* 2013;17:263–72.
30. Robinson JK, Dayal MB, Gindoff P, Frankfurter D. A novel surgical treatment for caesarean scar pregnancy: laparoscopically assisted operative hysteroscopy. *Fertil Steril* 2007;92:1497.e13–6.
31. Jiang S, Zhao S. Laparoscopic surgery for ectopic pregnancy within a caesarean scar. *Clin Exp Obstet Gynecol* 2013;40: 440–4.

Office Hysteroscopy Revisited

Shikha Sharma¹, Anamika Das², Sadia Mansoor², Kallol Kumar Roy³

¹Fellow, MIGS, ²Senior Resident, ³Professor and Head of MIGS Division, AIIMS, New Delhi

Introduction

Office hysteroscopy involves the use of miniaturized endoscopic equipment (2.7 mm scopes with a 3-3.5 mm outer sheath) to directly visualize the uterine cavity, without the need for formal theatre facilities or general or regional anaesthesia. It is indicated primarily in the assessment of abnormal uterine bleeding and diagnostic work-up of reproductive problems. More recently, advances in endoscopic technology and ancillary instrumentation have allowed operative hysteroscopic procedures in an office setting. Common procedures include diagnostic hysteroscopy, lysis of intra-uterine adhesions, removal of retained products of conception, endometrial polypectomy, removal of small submucous fibroids, endometrial ablation, removal of lost intrauterine devices and transcervical sterilization and metroplasty.

The appropriate surgical technique, allied to pain control, allow Office Hysteroscopy to resolve more than 90% of the intra-uterine pathology, thus being an important contribution to patient safety. The future is leaving OR environment and moving towards ambulatory and Office Hysteroscopy procedures

Procedure Preparation

Transferring all hysteroscopic surgeries as in-office procedures requires better and more elaborate planning and preparation.

A. Comfortable setting: Outpatient hysteroscopy, should, ideally be conducted outside of the formal operating theatre setting in an appropriately sized, equipped and staffed treatment room with adjoining, private changing room and toilet. This may be a dedicated hysteroscopy suite or a multi-purpose facility. Anxiety increases the degree of discomfort experienced therefore, the patient should be provided adequate emotional support ('vocal local').

B. Pain: Is the primary reason for failure of office hysteroscopy, it is paramount that strategies for pain management in the office setting be in place regardless of the technique and instrumentation used.

Opioids- No proven benefit in terms of pain control and woman's satisfaction over local anaesthesia. Use not recommended.

Anxiolytics- Not recommended

NSAIDs- 400mg of Ibuprofen or 1000mg of Paracetamol may be taken approximately an hour before the procedure particularly in units offering simultaneous hysteroscopic diagnosis and treatment ('see and treat' clinics).

Paracervical Block- Reduces the mean pain score both during and 30 minutes after the procedure, although it is clinically insignificant. Also, not routinely indicated to reduce the incidence of vasovagal reactions.

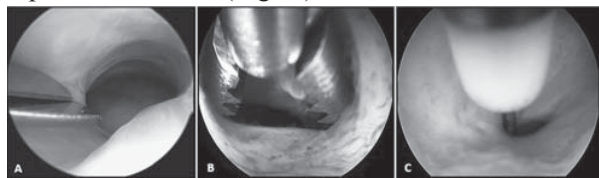
Local analgesia- Options include lidocaine sprays, gels, and creams that can be applied to the cervix when tenaculum is used, but studies have shown inconsistent wait times before the procedure can be initiated. Moreover, these topical agents address only superficial pain receptors and not those arising from uterine distension.

C. Cervical preparation: Routine cervical preparation is not recommended for office hysteroscopy. In pre-menopausal women with cervical stenosis, cervical softening with 400-800 of prostaglandin E1 administered vaginally 12 hours before the procedure effectively reduces subjective outcomes of pain. This is not routinely recommended.

In post-menopausal women with cervical stenosis, pretreatment with 25 of vaginal estradiol for 2 weeks in combination with 400 of misoprostol 12 hours before the procedure facilitates the passage of hysteroscope through the cervical canal. Misoprostol administration without supplemental estradiol is of limited value in postmenopausal women.

D. Overcoming Cervical Stenosis: Main risk factor for predicting hysteroscopic failure is cervical stenosis due to personal circumstances (such as nulliparity, post- menopausal status, or progestin contraception users) or anatomical variations (such as previous cervical surgery). For moderate stenosis, semirigid 5F mechanical instruments may be inserted in the operating channels of the modern rigid and the fibrous ring may be cut at two or three points using sharp scissors (Fig. A) or may be stretched by grasping forceps inserted within it with the jaws closed and then gently opened (Fig B). Bipolar electrodes are being used more in the case of stenosis of external uterine orifice (EUO) alone or in combination with

stenosis of the internal uterine orifice (IUO). Severe stenosis of the EUO may be resolved by creating three or four radial incisions, at approximately 3o'clock, 6o'clock, 9o'clock and 12o'clock positions using bipolar electrodes. (Fig. C)



E. Distension medium: Uterine distension with normal saline is more comfortable, quicker, cost-effective and provides a superior view of intra-uterine bleeding. Furthermore, the vaginoscopic approach is much easier with liquid distension. Recent studies, also suggest the role of warming the normal saline to 38-40 for pain reduction in office hysteroscopy. Liquid distension medium is kept at the constant uterine pressure 70mmHg so as to allow a clear intra-uterine view while also keeping it safe. Operative office hysteroscopy, using bipolar electrosurgery, requires normal saline both as distension as well as conducting medium.

F. Patient selection: There are some procedures which are ideal for see-and-treat, thanks to the 5-Fr working channel of any available hysteroscope and a grasping forceps:

- Targeted biopsy sampling
- Endometrial polypectomy
- Removal of small submucous leiomyomas
- Lysis of intra-uterine synechiae
- Removal of retained products of conception
- Metroplasty
- Retrieval of dislodged IUD / foreign body

Instrumentation

Although the resectoscope (Karl Storz, Germany), is the best option for major hysteroscopic procedures thanks to its diameter and variety of electrodes, such as big myomectomies and wide lysis of adhesions, the introduction of smaller devices ranging from 3 to 6 mm caliber has allowed the possibility of displacing many indications from OR to OH settings. Typically, endometrial polyps are the lesions which can be more easily removed in a quick and safe office procedure in the vast majority of cases, showing removal success rates ranging from 80% till 96%.

The Bettocchi® hysteroscope (Karl Storz, Germany) allows using microscissors, grasping forceps (Fig. D), hook (Fig. E) and biopsy forceps, removal loops, and

tubal occlusion devices for permanent contraception. Besides, it takes advantage of the bipolar electrodes (Gynecare Versapoint™ Bipolar Electrosurgery System, Ethicon).

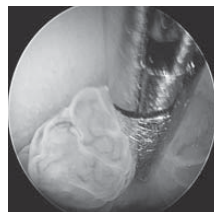

Fig. D

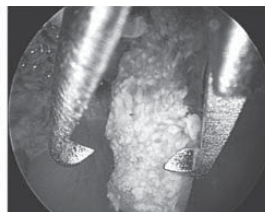


Fig. E

Smaller calibers have also benefitted modern 16 Fr bipolar resectoscopes (Fig. F) due to its cutting and coagulating electrodes. The newest mechanical tissue morcellators (Truclear System, Smith & Nephew, USA) and Myosure (Hologic, USA) allow quick OH procedures without the need of a long-lasting curve, which makes them ideal instruments for less experienced endoscopists, as well as the efficacy keeps steady with the lowest recurrence rate.

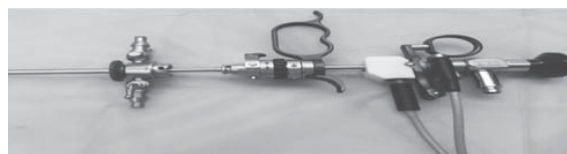

Fig. F. 16 Fr Bipolar Resectoscopes



Fig. G. Myosure®: complete system with generator, hysteroscope and disposable rotating internal system.

Growing calibers allow more complex and longer surgeries without leaving the Office; 5.0 and 8.0 options for the Truclear System® and LITE, CLASIC, and XL diameters for Myosure® (Fig. G) Indications are removal of any organic pathology, such as endometrial polyps, complete submucous myomas and retained products of conception.

Since the introduction of laser in hysteroscopy in the 70s and 80s in the USA, more advanced systems have been developed. The diode laser (Biolitec, Germany) introduces the EVOLVE® Dual Laser and Twister™ fibers. Its dual wavelength laser machine can vaporize and/or enucleate organic pathologies (endometrial polyps and G0– G1 myomas) from the uterine cavity without harming the surrounding tissue. The main

advantages are avoidance of most of pain, low relapse rate, and high patient satisfaction compared with the electrical bipolar procedure. The results do not seem to be related to size or number of pathology, and a 12-month follow-up shows both the lowest recurrence and complications rates.

Endometrial resection and/or ablation to manage heavy menstrual bleeding have decreased their indications since the introduction of levonorgestrel (LNG) releasing system (Mirena® and Jaydess®, Bayer, Germany) in the early 90s. The efficacy of intrauterine LNG has brought a new choice to improve quality of life during menstrual period beyond surgery. However, some nonnegligible effects such as breast tenderness, hypertension, weight increase, and mood changes are responsible for it being rejected by some women. Besides, the worldwide increase of laparoscopic hysterectomy has left a narrow space for hysteroscopic treatment of menorrhagia. However, in patients with normal-sized uterus, once malignancy has been ruled out and hormonal or when surgical adverse events want to be avoided, endometrectomy or endometrial ablation is a cost-effective treatment with short recovery and scarce complications rate.

First-generation techniques were developed through the use of the resectoscope of the Nd-YAG laser around the 1980s, but general anesthesia was required. Further second-generation techniques with balloons, heat-free fluid, cryotherapy, radiofrequency, or photodynamics have allowed for simpler and quicker procedures that can also be applied as OH procedures with the help of paracervical anesthesia. The learning curve is short, the clinical results are as good as with first generation, and a prior endometrial biopsy is still more mandatory as remaining tissue will be burnt.

Latest Buzz in Office Hysteroscopy

1. Parryscope: Similar to hysterosalpingo contrast sonography (HyCoSy), mixture of saline and ambient air was instilled into the uterus with iv tubing connected to a saline bag using a flexible 2.9 mm hysteroscope (47). Whole tubal occlusion was predicted with 98.3% to 100% sensitivity and 69.5% to 83.75% specificity compared to laparoscopy
2. Cryoprobe: It has been designed on the idea of Jacek Doniec, Gynaecologist at the Military Institute of medicine in Warsaw, Poland. It is appropriate to be used with a hysteroscope of a diameter of 4-5mm with a working channel of 5Fr, and combines the functions of grasping and

resecting due to the low temperatures at the tip of the tool. Such cryobiopsy allows removing larger fragments of tissue from the uterine cavity, both hard and soft along with a lower risk of bleeding due to the haemostatic features of cryotechnology (48). The pathological structure is attached to the pointy end of the electrode owing to the adhesive force created by reducing the temperature to -70°C. This adherence is created within a few seconds and lasts only during the freezing stage.

3. Endosee System: It is an All-in-one, handheld, portable, cordless system which is simple, quick to set up, needs only minimal staff training. It is a lightweight reusable handset that has a single-use, flexible, thin (<5mm) sterile cannula and uses a new camera and light source every time so there's no degradation in visualization. There is a bright, 3.5-inch touch-screen color LCD capable of both still image and video capture with a channel for fluid infusion, complete with a dock for battery charge and data transfer with a rechargeable battery that lasts more than 2 hours.



Conclusion

- Practice the technique (particularly vaginoscopy) in the OR while the patient is asleep. Once the cervical canal is easily identified, attempt the technique in the office while the patient is awake.
- Begin with simple procedures to build confidence and expertise like diagnostic hysteroscopy, small endometrial polypectomy, visually directed biopsy, and removal of lost IUD strings.
- Train a team in the office for equipment setup and processing. The hysteroscopes are small and fragile but can last for decades if handled properly.
- Use the minimal distention pressure needed for adequate visualization to reduce patient discomfort. Use only physiological distention media. Do not perform any procedure that requires >3 L of fluid unless a weighted monitoring system is available.
- Have a crisis checklist and practice each crisis with your team.

- Be prepared to have your patients be amazed that you can perform the procedure in the office with no speculum, tenaculum, or anesthesia, and that they can leave the clinic and promptly return to normal activities. With 5-mm hysteroscopes, we do not recommend pelvic rest.

Suggested Reading

1. Di Spiezio Sardo A, Calagna G, Di Carlo Costantino. Tips and Tricks in office Hysteroscopy. *Gynecol Minim Invas Therap*.2015;4:3-7.
2. Di Spiezio Sardo A, Bettocchi S, Bramante S, Guida M, Bifulco G, Nappi C. Office vaginoscopic treatment of an isolated longitudinal vaginal septum: a case report. *J Minim Invasive Gynecol*. 2007;14:512e515.
3. Pontrelli G, Landi S, Siristatidis CH, Di Spiezio Sardo A, Ceci O, Bettocchi S. Endometrial vaporization of the cervical stump employing an office hysteroscope and bipolar technology. *J Minim Invasive Gynecol*. 2007;14:767e769.
4. Di Spiezio Sardo A, Bettocchi S, Spinelli M, et al. Review of new office-based hysteroscopic procedures. *J Minim Invasive Gynecol*. 2010;17: 436-448.
5. Bettocchi S, Ceci O, Spinelli ML, et al. Office hysteroscopy. *Ref Gynecol Obstet*.2010;12:1-9.
6. Salazar CA, Isaacson KB. Office Operative Hysteroscopy: An Update. *J Minim Invasive Gynecol*.2018;25:199-208
7. Cicinelli E. Diagnostic mini-hysteroscopy with vaginoscopic approach: ratio- nale and advantages. *J Minim Invasive Gynecol*. 2005;12:396e400.
8. Van Dongen H, de Kroon CD, Jacobi CE, Trimbos JB, Jansen FW. Diagnostic hysteroscopy in abnormal uterine bleeding: a systematic review and meta-analysis. *BJOG* 2007; 114:664-75.
9. Litta P, Cosmi E, Saccardi C, Esposito C, Rui R, Ambrosini G. Outpatient operative polypectomy using a 5mm hysteroscope without anaesthesia and/or analgesia: advantages and limits. *Eur J Obstet Gynecol Reprod Biol* 2008;139:210-4
10. Marsh FA, Rogerson LJ, Duffy SR. A randomized controlled trial comparing outpatient versus daycare endometrial polypectomy. *BJOG* 2006;113:896-901.
11. Prasad P, Powell MC. Prospective observational study of Thermablate Endometrial Ablation System as an outpatient procedure. *J Minim Invasive Gynecol* 2008;15:476-9.
12. Andersson S, Mints M. Thermal balloon ablation for the treatment of menorrhagia in an outpatient setting. *Acta Obstet Gynecol Scand* 2007;86:480-3.
13. Sinha D, Kalathy V, Gupta JK, Clark TJ. The feasibility, success and patient satisfaction associated with outpatient hysteroscopic sterilization. *BJOG* 2007;114:676-83.
14. Choksuchat C, Cheewadhanaraks S, Getpook C, Wootipoom V, Dhanavoravibul K. Misoprostol for cervical ripening in non-pregnant women: a randomized double-blind controlled trial of oral versus vaginal regimens. *Hum Reprod* 2006; 21:2167-70.
15. Crane JM, Healey S. use of misoprostol before hysteroscopy: a systematic review. *J Obstet Gynaecol Can* 2006; 28:373-9.
16. Campo R, Molinas CR, Rombauts L, et al. Prospective multicentre randomized controlled trial to evaluate factors influencing the success rate of office diagnostic hysteroscopy. *Hum Reprod*. 2005;20:258e263.
17. Pluchino N, Ninni F, Angioni S, et al. Office vaginoscopic hysteroscopy in infertile women: effects of gynecologist experience, instrument size, and distention medium on patient discomfort. *J Minim Invasive Gynecol*. 2010;17: 344e350.
18. Cooper NA, Smith P, Khan KS, Clark TJ. A systematic review of the effect of the distension medium on pain during outpatient hysteroscopy. *Fertil Steril*. 2011;95:264-271.
19. Tawfek ME, Hemeda HM, Ibrahim MA. Effectiveness of warm saline distension media on relieving pain in outpatient office hysteroscopy: A randomized controlled trial. *J Gynecol Reprod Med*. 2019;3:1-7.
20. Guide M, Di Spiezio Sardo A, Acunzo G, et al. Vaginoscopic versus traditional office hysteroscopy: a randomized controlled study. *Hum Reprod*. 2006; 21: 3253e3257.
21. Cooper NA, Smith P, Khan KS, Clark TJ. Vaginoscopic approach to outpatient hysteroscopy: a systematic review of the effect on pain. *BJOG*. 2010;117: 532e539.
22. Gkrozou F, Dimakopoulos G, Vrekoussis T, et al. Hysteroscopy in women with abnormal uterine bleeding: a meta-analysis on four major endometrial pathologies. *Arch Gynecol Obstet*. 2015; 291:1347-1354.
23. Rovira Pampalona J, Degollada Bastos M, Mancebo Moreno G, Ratia Garcia E, Buron Pust A, Mateu Pruñonosa JC, Guerra Garcia A, Carreras Collado R, Bresco Torras P. Outpatient hystero- scopic polypectomy: bipolar energy system (Versapoint®) versus mechanical energy system (TRUCLEAR System®)—preliminary results. *Gynecol Obstet Invest*. 2015;80(1):3–9.
24. Noventa M, Ancona E, Quaranta M, Vitagliano A, Cosmi E, D'Antona D, Gizzo S. Intrauterine morcellator devices: the icon of hysteroscopic future or merely a marketing image? A systematic review regarding safety, efficacy, advantages, and contraindications. *Reprod Sci*. 2015;22(10):1289–96.
25. Lara-Domínguez MD, Arjona-Berral JE, Dios-Palomares R, Castelo-Branco C. Outpatient hysteroscopic polypectomy: bipolar energy system (Versapoint®) versus diode laser—randomized clinical trial. *Gynecol Endocrinol*. 2016; 32(3): 196–200.
26. Haimovich S, López-Yarto M, Urresta Ávila J, Saavedra Tascón A, Hernández JL, Carreras Collado R. Office hysteroscopic laser enucleation of submucous myomas without mass extraction: a case series study. *Biomed Res Int*. 2015;2015:905204.
27. Nappi L, Pontis A, Sorrentino F, Greco P, Angioni S. Hysteroscopic metroplasty for the septate uterus with diode laser: a pilot study. *Eur J Obstet Gynecol Reprod Biol*. 2016; 206:32–5.
28. Nappi L, Sorrentino F, Angioni S, Pontis A, Greco P. The use of laser in hysteroscopic surgery. *Minerva Ginecol*. 2016;68(6):722–6.
37. Rioux JE. The intrauterine device today. *J SOGC*. 1993; 15(8): 921–4.
38. Coleman M, McCowan L, Farquhar C. The levonorgestrel-releasing intrauterine device: a wider role than contraception. *Aust N Z J Obstet Gynaecol*. 1997;37(2):195–201.

Journal Scan

Preeti Deedwania, Nilofar Noor

Senior Resident, Department of Obstetrics & Gynecology, All India Institutes of Medical Sciences, New Delhi

1. *Journal of Minimally Invasive Gynecology* (2019) 26:856–864

Laparoscopic-Assisted Myomectomy with Bilateral Uterine Artery Occlusion/Ligation

Paul MacKoul, Rupen Baxi, Natalya Danilyants, Louise Q. van der Does, Leah R. Haworth and Nilofar Kazi

Study Objective: Conventional laparoscopic myomectomy (CLM) and robotic-assisted myomectomy (RAM) are limited in the number and size of myomas that can be removed, whereas abdominal myomectomy (AM) is associated with increased complications and morbidity. Here we evaluated the surgical outcomes of these myomectomy techniques compared with those of laparoscopic-assisted myomectomy (LAM), a hybrid approach that combines laparoscopy and mini-laparotomy with bilateral uterine artery occlusion or ligation to control blood loss.

Design: Retrospective chart review (Canadian Task Force classification II-1). Setting: Suburban community hospital. Patients: Women age ≥ 18 years with nonmalignant indications. Intervention: A total of 1313 consecutive CLMs, RAMs, AMs, and LAMs performed between January 2011 and December 2013.

Measurements and Main Results: Our review included 163 CLMs (12%), 156 RAMs (12%), 686 AMs (52%), and 308 LAMs (23%). Although the average number, size, and total weight of leiomyomas removed were comparable in the LAM and AM groups (9.1, 8.13 cm, and 391 g, respectively, vs 9.0, 7.5 cm, and 424 g; $p < .0001$), the number and weight of myomas were significantly greater in those 2 groups compared with the CLM and RAM groups (2.9 and 217 g, respectively, and 2.9 and 269 g; $p < .0001$). The intraoperative complication rate was highest in the RAM group, and the postoperative complication rate was highest in the AM group, both of which were approximately 3 times greater than the rates in the LAM group. There was no statistically significant difference in postoperative complication rates between the CLM and LAM groups.

Conclusion: LAM with uterine artery occlusion/ligation is a viable approach for removing large tumor loads while minimizing blood loss and precluding the need for power morcellation.

Comments: Myomectomies are one of the most common gynecological surgeries performed worldwide. Laparoscopy assisted myomectomy (LAM) has advantage over conventional laparoscopic or robotic myomectomy as this technique provides opportunity to palpate the uterus. Smaller deep-seated myomas can be detected and removed, thereby reducing the risk of recurrence. Another advantage of LAM is elimination of need of power morcellation. LAM has all the advantages of abdominal myomectomy, including blood loss preventing measures like uterine artery occlusion or ligation making it even better. We still need more randomized multi centre trials on these blood loss-controlling techniques.

2. *Journal of Minimally Invasive Gynecology* (2019) 26, 618–627

Hysteroscopic Resection of Endometrial Polyps and Assisted Reproductive Technology Pregnancy Outcomes Compared with No Treatment: A systematic review

Huixia Zhang, Xueqing He, Wenyan Tian, Xueru Song, Huiying Zhang

Summary: Endometrial polyps are frequently encountered in the uterine cavity of infertile women. There is much debate regarding the treatment of endometrial polyps in patients who are undergoing assisted reproductive technology (ART). A systematic review was performed by searching PubMed, Embase, and the Cochrane Library for retrospective or prospective studies that compared the effect of hysteroscopic resection of polyps with no treatment on pregnancy outcomes of patients who underwent ART. The primary outcomes were clinical

pregnancy, live birth, miscarriage, and implantation rates after ART. Eight studies with a total of 2267 patients were included. The results showed that hysteroscopic resection of endometrial polyps (mean size <2 cm) was associated with an increased rate of clinical pregnancy in patients who underwent intrauterine insemination. No clear benefit was observed for clinical pregnancy, live birth, miscarriage, or implantation rates in patients who underwent in vitro fertilization/intracytoplasmic sperm injection cycles. In conclusion, the effect of hysteroscopic polypectomy on pregnancy outcomes of patients who have undergone ART remains unclear. More prospective, randomized controlled trials are warranted to determine appropriate treatment.

Comments: Endometrial polyps are the polypoidal outgrowth arising from endometrial lining containing endometrial glands, stroma and blood vessels. Presence of endometrial polyp is more frequent in infertile women, which makes it a possible causative factor for infertility. Existing literature has varying opinion on management of endometrial polyps especially when the mean size of polyp is < 2 cm. This systematic review shows that for polyps <2 cm there is no clear benefit of hysteroscopic polypectomy in terms of clinical pregnancy rate, live birth rate, miscarriage rate and implantation rate in ART cycles. Further randomized studies are needed to clarify the results.

Congratulations !!

Dr Mitra Saxena for correctly answering the Crossword and Pictorial Quiz of September issue

Answer: September Issue

Crossword

Horizontal clues:

1. Mifepristone
2. Wamstekar
3. Ulipristal
4. MRI
5. Palmcoein
6. Vonwillebrand
7. Osada
8. Metronidazole

Vertical clues:

- a. Whiff
- b. Clue
- c. Trichomoniasis
- d. UAE
- e. Elagolix
- f. Junctional
- g. Liver

Pictorial Quiz

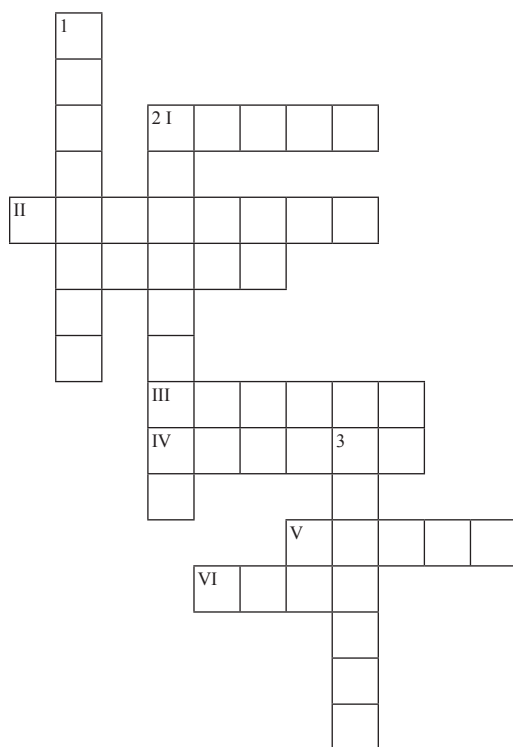
1. TVS
2. Hydrosalpinx

The Maze of Knowledge

Garima Patel, Vidushi Kulshrestha

Department of Obst. Gynaec. and Urogynaecology, AIIMS, New Delhi

CROSSWORD



Across

- I. How many degrees of freedom are possible in robotic surgery.

- II. Besides decrease in ovarian reserve, what is the other main complication of laparoscopic ovarian drilling. _____
- III. Point 3cm below left costal margin in the midclavicular line just lateral to rectus muscle, which is used to create pneumoperitoneum. _____
- IV. Hysteroscopy using 2.7 mm scope without any anaesthesia is _____ hysteroscopy.
- V. While performing endometriotic cystectomy, which site leads to the maximum loss of ovarian reserve. _____
- VI. First manual morcellation was reported by which surgeon?

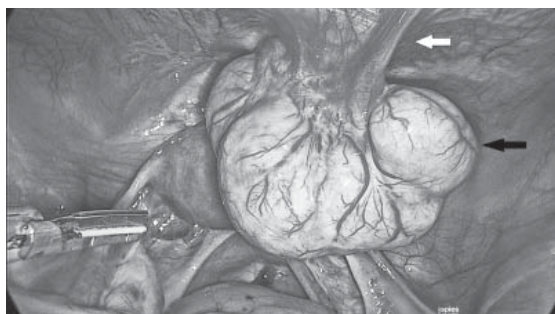Down

1. Sign which differentiates the early phase of a miscarriage from caesarean scar ectopic: _____ sign”
2. In robotic surgery, it is important to keep a sufficient distance between camera arm remote center and the patient cart tower. Otherwise, optimal range of motion will be impaired. This process is called setting up the _____.
3. Probable theory for port site metastasis is due to which effect of CO2 pneumoperitoneum: _____ effect

PICTORIAL QUIZ

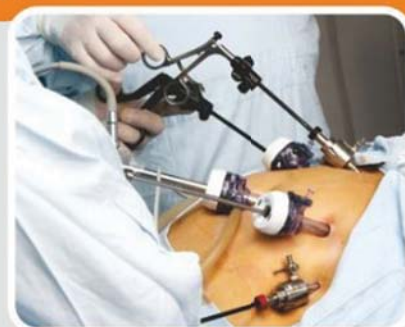Q1. Identify

Q2. What is the most probable cause leading to this condition?



Whatsapp your answers to **9211656757**.
Names of first three correct entries will be mentioned in the next issue

Refer page 57 for previous answer key.



**WHEN IT COMES TO YOUR HEALTH
TRUST THE HOSPITAL WHICH HAVE
EXPERTISE & EXPERIENCE !**

SPECIALIST IN GYNAE KEYHOLE SURGERIES FOR:

- *Gynaecologic Cancer*
- *Removal of Fiberoids*
- *Laparoscopic Encerclage & TAC
(Laparoscopic Encerclage for
Recurrent Miscarriages)*

GYNAE LAPROSCOPIC FOR:

- *Ovarian Cysts*
- *Urinary Incontinence*
- *Endometriosis and Painful
Periods*
- *Heavy and Abnormal
Menstural Bleeding*

SPECIALIST IN IVF AND INFERTILITY

Dr. Nikita Trehan



Consultant
GYNAE
Laparoscopic
Surgeon

Dr. Hafeez Rahman



Consultant
GYNAE
Laparoscopic
Surgeon

Dr. Astha Gupta



Consultant
IVF &
Infertility

AWARDED

**World Record of Largest
Uterus removal done
Laparoscopically (9.6 kgs)**

**World Record of Largest
Fabroid removed
Laparoscopically (6.5 kgs)**

F-1 Kalindi Colony, New Delhi 110065

☎ 011-4882 0000, 9810157410

helpdesk@sunrisehospitals.in

• Delhi • Dubai • Mumbai • Kochi

With Best Compliments

EndoReg[®]
Dienogest Tablet 2 mg

Endometriosis Regression at its Best

LycoRed[®]
Softgel Cell Protector

Essential for growing Fetus

Yuliprist[™]
Ulipristal Acetate Tablet 5 mg

Save her Uterus

Maintane[®] 500/250
Injection 17 α - Hydroxyprogesterone caproate

Nourish the dream of Motherhood

Cystelia-M[™]
Myo-Inositol 1.1 gm, D-Chiro-Inositol 27.6 mg (40:1),
L-methylfolate 1 mg, Vitamin D3-1000 IU Tablet

Comprehensive Treatment for PCOS

JP Tone[®]
Syrup Iron + Zinc + Vit. B complex

Supports Pregnancy Restores Vitality

Cystelia 35[™]
Cyproterone Acetate 2 mg +
Ethinylloestradiol 35 mcg Tablet

The Most Effective OC Pill for PCOS

CycloReg[®]
Tablet Norethisterone - 5

Control Bleeding, Regulate Cycles

Divagest[™] SR 200/300
Progesterone Sustained Release Tablet 200/300 mg

Provides optimum Luteal Phase Support

Doxypal[®] DR-L
Capsule (Doxycycline-100 mg + Lactic Acid Bacillus- 5 billion spores)

Antibiotic with Least Reported Resistance

NAARI
A division of JAGSONPAL

Jagsonpal Pharmaceuticals Ltd.
T-210 J, Shahpur Jat, New Delhi, Delhi 110049